

Brachial Plexus Anesthesia

There are four approaches to the brachial plexus. These include the interscalene, supraclavicular, infraclavicular, and axillary approach. For the purposes of this lecture we will concentrate on the interscalene and axillary approach. Traditional techniques as well as the use of a peripheral nerve stimulators will be described. The approach to brachial plexus anesthesia is largely dependent upon the surgical procedure. Each approach may “miss” a nerve distribution requiring supplementation. Peripheral nerve blocks at the elbow, wrists, and digits can supplement the missed nerve, as well as be used for minor surgical procedures of the hand and fingers.

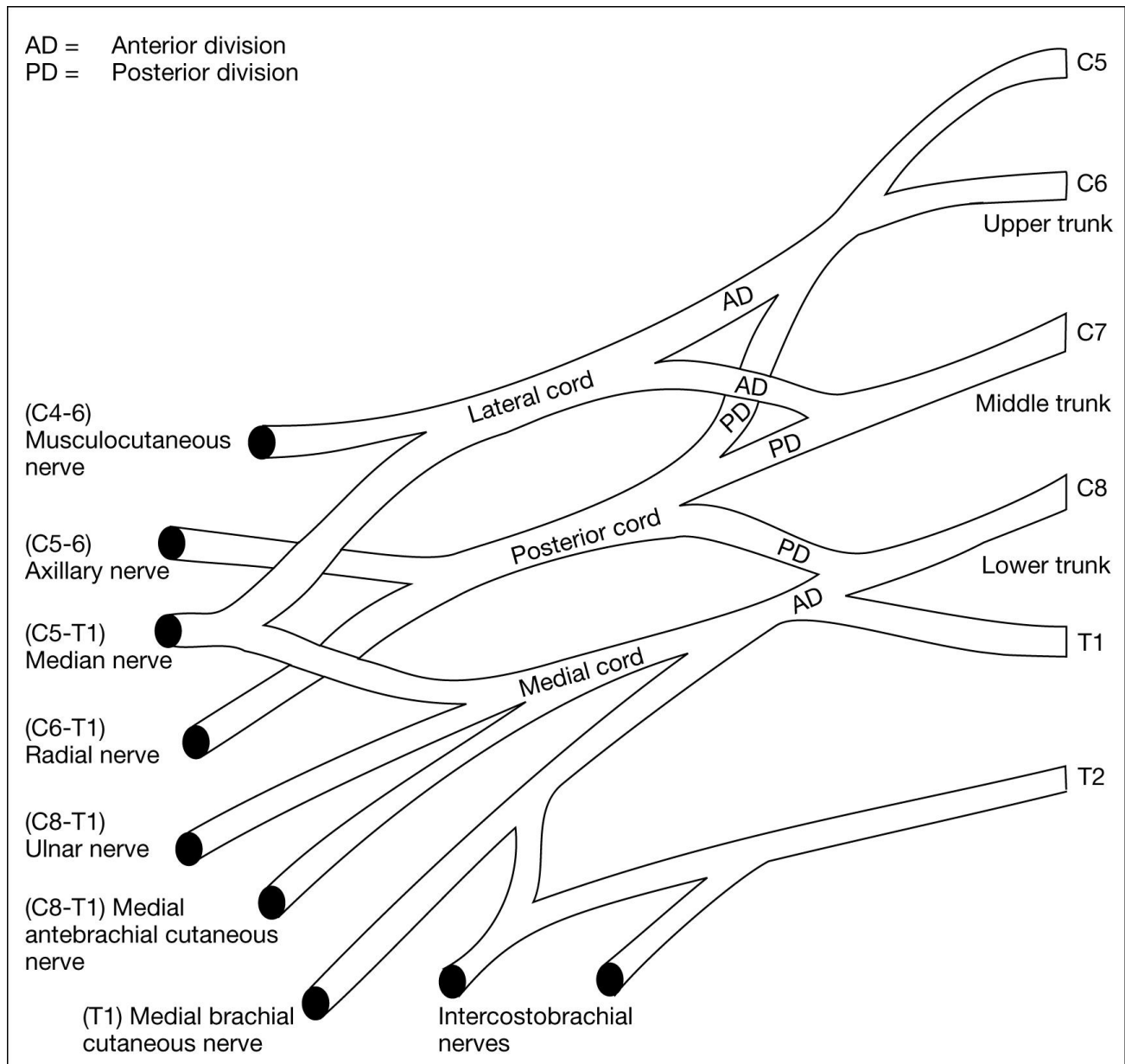
Anatomical Consideration and Brachial Plexus Anesthesia

The brachial plexus is created by distributions from C5 to T1. Blockade of the brachial plexus can provide surgical anesthesia of the hands, upper/lower arm, and shoulder depending on the approach. A thorough knowledge of anatomy and its impact on the two techniques is important for success. Peripheral nerve blocks may be required to supplement brachial plexus anesthesia. For example, when a tourniquet is used, the medial brachial cutaneous (C8-T1) and intercostobrachial (T2) should be blocked to prevent tourniquet pain. The medial brachial cutaneous and intercostobrachial nerve innervate the medial and posterior portions of the proximal arm and are not located within the brachial plexus sheath. The medial brachial cutaneous nerve leaves the sheath just below the clavicle. For shoulder surgery, a portion of the anterior shoulder is innervated by the superficial cervical plexus (C1-C4). A field block, along the posterior border of the sternocleidomastoid will effectively block the superficial cervical plexus.

Additional anatomical considerations will be discussed with each technique.

Anatomy

The anatomy of the brachial plexus is relatively complicated. The brachial plexus is primarily formed by ventral rami of C5-T1. C4 and T2 make minor contributions.



This is the most common anatomical configuration. Variation may occur among patients.

Contributions from C5-T1 come together, then separate to form trunks, divisions, cords, and main branches. At the level of the anterior and middle scalene muscles the trunks are already formed.

Upper Trunk C5-6
Middle Trunk C7
Lower Trunk C8-T1

Upper, middle, and lower trunks course over the lateral border of the first rib and under the clavicle. At this point, each trunk will separate into anterior and posterior divisions. As the brachial plexus

emerges under the clavicle, the anterior and posterior divisions come together to form three cords. The lateral cord is lateral to the axillary artery; the posterior cord is located posterior to the axillary artery; and the medial cord is located medial to the axillary artery.

Lateral Cord: formed by anterior divisions of the upper and middle trunks.
--

Posterior Cord: formed by posterior divisions of all three trunks.
--

Medial Cord: formed by anterior division of the lower trunk.
--

At the lateral border of the pectoralis minor muscle, each cord divides into branches, terminating in individual nerves.

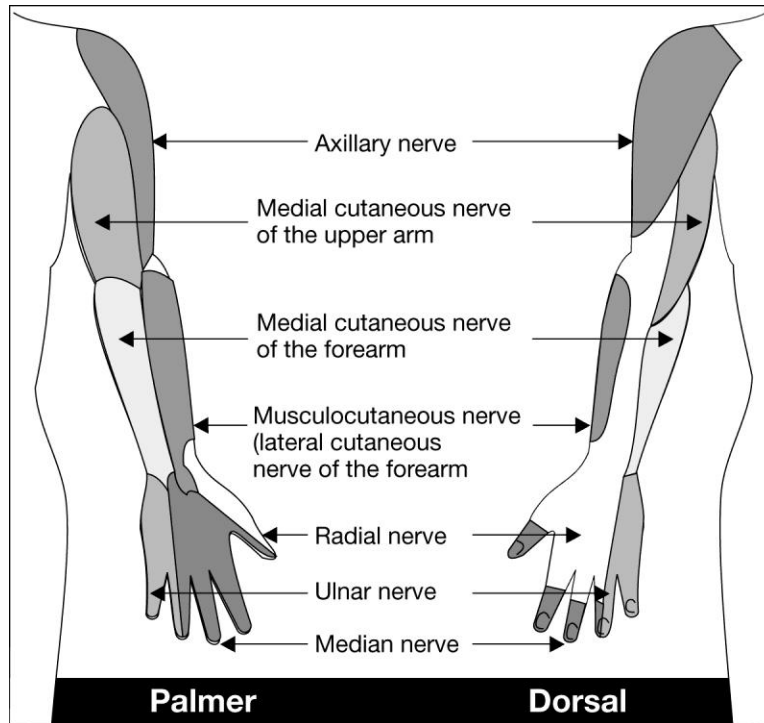
Lateral Cord: divides into the lateral branch of the median nerve and terminates in the musculocutaneous nerve.

Posterior Cord: divides into the axillary nerve and terminates in the radial nerve.

Medial Cord: divides into the medial branch of the median nerve and terminates in the ulnar nerve.
--

The brachial plexus is enveloped by a fascial sheath, formed by prevertebral and scalene fascia, extending from the intervertebral foramina to the upper arm. The formation of a sheath allows for the administration of brachial plexus anesthesia. Injection into the sheath, at any anatomical point, will allow for the spread of local anesthetics and subsequent blockade. Each approach to the brachial plexus impacts specific anatomical areas of the upper extremity. Choice of a specific technique should be made based on the surgical procedure.

Cutaneous Nerve Supply of the Arms



This is the most common anatomical configuration. Variation may occur among patients.

Major Motor Function of the Individual Nerves of the Brachial Plexus

Nerve	Major Motor Function
Axillary Nerve	Abduction of the shoulder
Musculocutaneous Nerve	Flexion of the elbow
Radial Nerve	Extension of the elbow, wrist, and finger
Median Nerve	Flexion of the wrist and finger
Ulnar Nerve	Flexion of the wrist and finger

Choosing a Technique for Brachial Plexus Blockade

The approach to brachial plexus anesthesia is based on anatomical knowledge and surgical procedure.

Interscalene Approach: excellent technique for surgical procedures on the shoulder, arm, and forearm. Intense block at C5-C7 and diminished blockade of C8-T1. Not a good technique for surgical procedures that involve the ulnar nerve distributions.

Axillary Approach: excellent technique for surgical procedures from the elbow to the hand. There is intense blockade of C7-T1. This approach is usually not adequate for the shoulder and upper arm (C5-6).

Interscalene Approach to the Brachial Plexus

Indications

The interscalene approach to the brachial plexus is a suitable technique for the following situations:

- Surgical procedures of the shoulder and upper arm
- Surgical procedures of the hand (will need to supplement the ulnar nerve distribution)
- Reduction of a dislocated shoulder, arm, and wrist fractures

Advantages & Disadvantages

Advantages of the interscalene approach include the following:

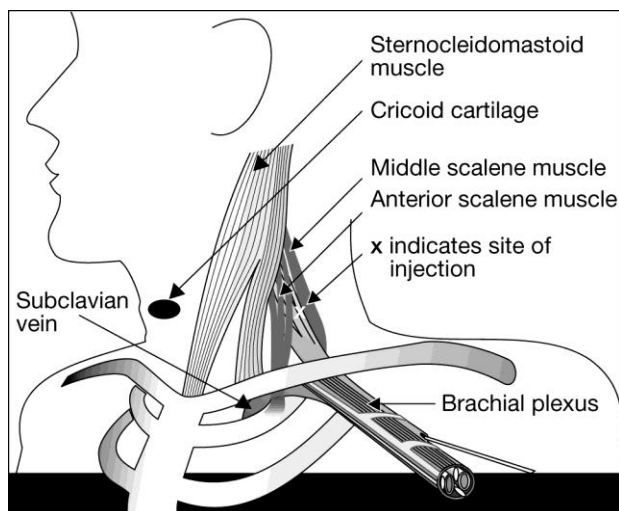
- Ability to perform surgical procedures of the shoulder and upper arm
- Avoiding complications associated with general anesthesia
- Muscle relaxation for the surgeon
- Postoperative analgesia
- Do not need to abduct the arm and flex at 90 degrees at the elbow

Disadvantages of the interscalene approach include the following:

- Moderate in complexity
- Need to supplement the ulnar nerve distribution for lower arm and hand surgery.
- Potentially serious complications can occur. Complications include inadvertent epidural/subarachnoid injection, vertebral artery injection, and pneumothorax.
- Common side effects may be distressing to the patient. These include blockade of the phrenic, recurrent laryngeal, vagus, and cervical sympathetic nerves.

Equipment

- Antiseptic solutions (i.e. betadine, hibiclens, and/or alcohol)
- 22 or 23 gauge, 4 cm, short beveled needle (for paresthesia technique)
- Nerve stimulator, a 22 gauge, 4 cm insulated short bevel needle if using a nerve stimulator technique
- Sterile towels or drapes

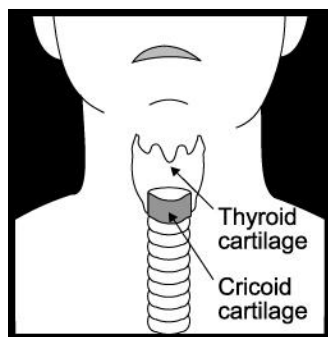


Technique

The upper, middle, and lower trunks of the brachial plexus are found between the anterior and middle scalene muscles. This is called the interscalene groove. The trunks are named based on their vertical arrangement within the interscalene groove. The interscalene groove is found at the level of the cricoid cartilage. The external jugular vein will cross the area of the interscalene groove at the level of the cricoid cartilage. A common mistake, when first attempting this approach, is to confuse the groove between the sternocleidomastoid and anterior scalene muscle. This groove is anterior

to the interscalene groove.

Identification of the interscalene groove is carried out by placing the patient supine. Ask the patient to turn their head 30 degrees or less towards the non-operative extremity. Identify the cricoid cartilage. Identify the posterior border of the sternocleidomastoid muscle. Slide your fingers posteriorly. The anterior scalene muscle will be noted just below the posterior edge of the sternocleidomastoid muscle. Just posterior to the anterior scalene muscle, the middle scalene muscle is located. The interscalene groove is located between the anterior and middle scalene muscles. If difficulties are encountered identifying the interscalene groove, have the patient lift their head against light pressure, and/or take a deep breath. This will help the anatomical structures to “stand out” and be identified. Place a skin wheal, insert a 22 gauge, 4 cm, short bevel needle perpendicular to the skin. Advance the needle medially and caudally (towards the feet) at a 45 degree angle until a paresthesia is evoked in the arm below the elbow. The needle should not be inserted more than 2.5 cm.



When using a nerve stimulator motor activity of the arm, wrist, or hand is desired. If stimulation of the phrenic nerve occurs needle placement is anterior to the brachial plexus. If stimulation of the deltoid or pectoralis muscles occurs needle placement is posterior. Stimulation should occur at or below 0.5 mA. If stimulation continues at 0.2 mA and less withdraw the needle slightly. Stimulation at this level may

indicate that the needle is intraneural.

Once the correct area is identified, a total of 30-40 ml of local anesthetic is injected. Frequent aspiration should occur during injection, ensuring an intravenous injection does not occur. Do not inject if the patient experiences pain or it is difficult to inject the local anesthetic. It is important not to exceed the maximum doses of local anesthetic. Digital pressure, applied proximally, may help with distal spread of the local anesthetic.

Local Anesthetics

Lidocaine, ropivacaine, and bupivacaine are commonly administered for the interscalene approach. Epinephrine will prolong the duration of action. An interscalene block, with lidocaine will have an onset of 5-15 minutes, an anesthetic duration of 3-6 hours, and provide analgesia for 5-8 hours.

Bupivacaine and ropivacaine will have an onset of 20-30 minutes, an anesthetic duration of 8-10 hours, and provide analgesia for 16-18 hours. Ropivacaine is a safer alternative to bupivacaine.

Complications

The complication rate for interscalene blocks is relatively high. The patient should be informed of what to expect and potential complications.

- The stellate ganglion, phrenic, and recurrent laryngeal nerve are near the brachial plexus. Patients with a history of chronic or acute pulmonary conditions should not have an interscalene block. The phrenic nerve is commonly blocked (ipsilateral 100% of the time) with this approach, which may result in respiratory failure. Horner's syndrome is common and may be distressing to the patient. Horner's syndrome manifests itself as miosis (contraction of the pupil), ptosis (drooping of the upper eyelid), and anhidrosis (diminished or absence of sweating). In addition, the patient may experience dyspnea and hoarseness.
- Intra-arterial injection may occur due to the proximity of the vertebral artery to the site of injection. Aspiration prior to and during injection is essential. A small dose of 1-3 ml will lead to seizures since the vertebral artery goes directly to the brain.
- Inadvertent venous injection will result in central nervous/cardiovascular system toxicity.
- Close proximity of the cervical neural foramina can result in an epidural, subarachnoid, or subdural injection.
- Pneumothorax can occur from inserting the needle too far laterally.

Axillary Approach to the Brachial Plexus

Indications

The axillary approach to the brachial plexus is suitable for the following:

- Surgical procedures of the lower arm and hand
- Reduction of lower arm, wrist, and hand fractures

Advantages & Disadvantages

Advantages of the axillary approach include the following:

- Ability to perform surgical procedures of the lower arm and hand
- Avoiding complications associated with general anesthesia
- Muscle relaxation for surgical purposes
- Postoperative analgesia
- Relatively low risk procedure
- Easy to master
- Arm must be abducted and flexed 90 degrees at the elbow

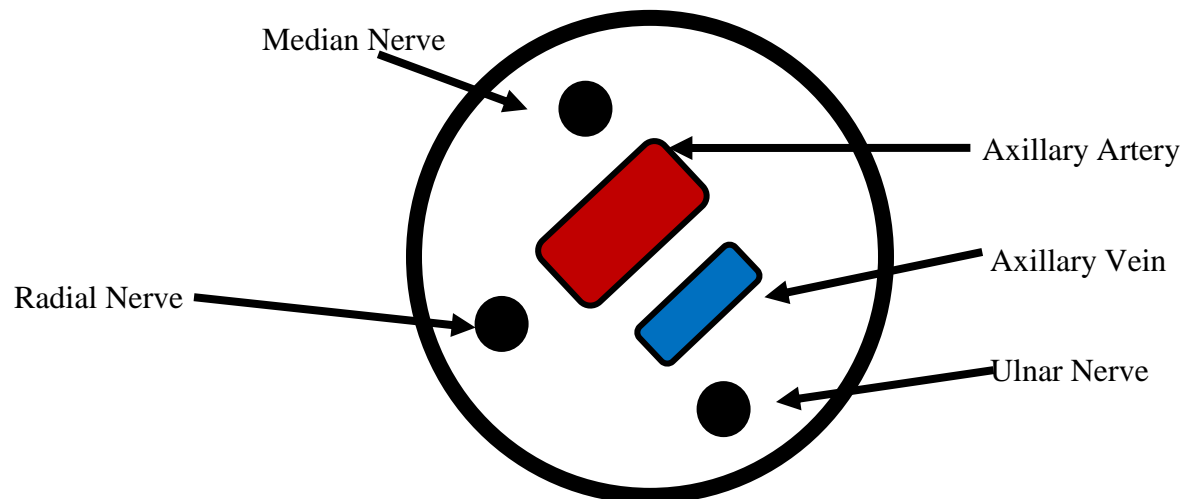
Disadvantages of the axillary approach include the following:

- May need to supplement "missed" nerve distributions
- Potentially serious complications (i.e. inadvertent intravascular injection and nerve injury)

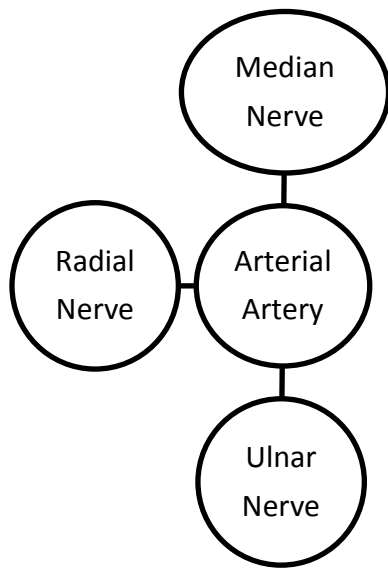
Anatomical Considerations

Beneath the clavicle, the subclavian artery becomes the axillary artery. The brachial plexus splits from upper, middle, and lower trunks into anterior and posterior divisions. The anterior and posterior divisions travel to the lateral border of the pectoralis minor and form the lateral, posterior, and medial cords. The cords split to form individual nerves that innervate the arm. The musculocutaneous nerve leaves the sheath prior to entering the axilla. The musculocutaneous nerve can be found within the coracobrachialis muscle, which is located immediately below the bicep. The musculocutaneous nerve should be blocked separately to ensure anesthesia. The brachial plexus sheath contains fascial sheaths and septa. This may result in patchy anesthesia by impeding spread of local anesthetic.

Knowledge of where each individual nerve is located within the sheath is important. The median nerve is superior to the axillary artery. The ulnar nerve is inferior to the axillary artery. The radial nerve is inferior and posterior to the axillary artery. The musculocutaneous nerve has already separated from the brachial plexus, traveling within the coracobrachialis muscle.



Schematic drawing of the contents of the brachial plexus sheath at the axilla



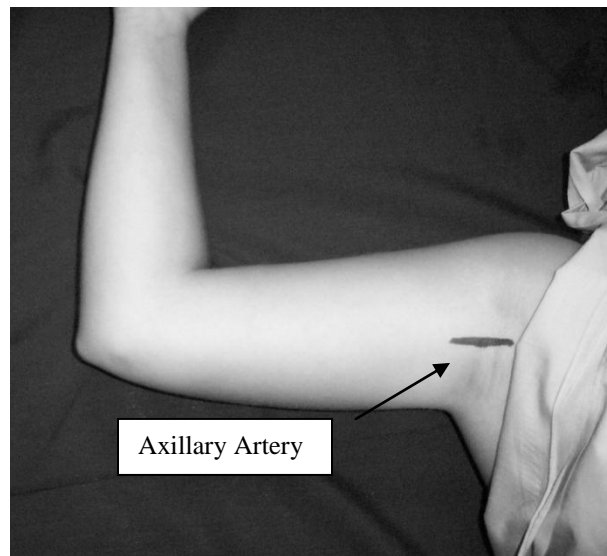
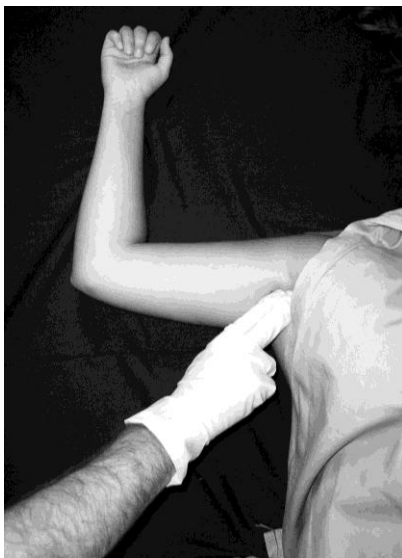Another technique is to picture anatomical structures as a wheel. The “hub cap” is the arterial artery identified by palpation. The top is the median nerve, bottom is the ulnar nerve, while the side is the radial nerve.

Equipment

- Antiseptic solutions such as betadine, hibiclens, and alcohol
- 22 or 25 gauge, 4 cm, short beveled needle (for paresthesia and transarterial techniques)
- Nerve stimulator, 22 gauge, 4 cm insulated short beveled needle if using a nerve stimulator technique
- Sterile towels or drapes

Technique

There are several approaches to the brachial plexus block at the axilla including transarterial and paresthesia.



Identification of the axillary artery is accomplished by palpation.

Transarterial Technique

1. Position patient supine with arm abducted and flexed 90 degrees at the elbow.
2. Palpate the axillary pulse as proximal in the axilla as possible.
3. Use a 22 or 25 gauge, 4 cm blunted needle. Advance it while aspirating.
4. Once blood is aspirated, either go “through” the artery or pull back out of the artery. Once aspiration is negative, inject a total of 35-40 ml of local anesthetic in a normal sized adult. Aspirate every 5 ml to ensure that the needle has not inadvertently entered an artery or vein. Monitor for signs and symptoms of intra-arterial injection including increased heart rate, “funny” metallic taste, faintness, seizures, etc. Some clinicians will inject half of the total local anesthetic dose posterior to the artery and the other half anterior to the artery. Ensure that the maximum dose of local anesthetic is not exceeded.
5. Distal pressure will help “push” the local anesthetic proximally.
6. Bring the arm down, hold pressure for up to 5 minutes. Ensure the patient does not have a hematoma forming.

Paresthesia Technique

1. Position patient supine with arm abducted and flexed 90 degrees at the elbow.
2. Palpate the axillary pulse as proximal in the axilla as possible.
3. Use a 22 or 25 gauge, 4 cm blunted needle. Advance it while aspirating.
4. Insert the needle towards the artery, but do not puncture it. If blood is aspirated, redirect the needle until a paresthesia is noted.
5. Knowledge of where each individual nerve is located within the sheath (as noted earlier in the schematic diagram of the brachial plexus sheath) is important.
6. Some clinicians choose any paresthesia of the arm or hand as an indication that they are in the sheath. Some will attempt to elicit a paresthesia in the operative distribution. Other clinicians will attempt to elicit a paresthesia in each distinct nerve distribution, injecting local anesthetic with each paresthesia.
7. Aspirate for blood prior to and during injection. It is important to ensure that the needle has not inadvertently entered a vessel. Do not continue to inject if the patient complains of pain or high injection pressures are required. Intra-neural injection can result in transient or permanent injury.

Nerve Stimulator Technique:

1. Position the patient supine with the arm abducted, flexed 90 degrees at the elbow.
2. Palpate the axillary pulse proximal in the axilla as possible.
3. Knowledge of where each individual is located within the sheath is essential. The median nerve is superior to the axillary artery.
4. Insert a 22 gauge, insulated needle. Aspirate for blood while you advance it.
5. Once stimulation of the hand is noted, in the appropriate distribution for the operation, inject 1 ml of local anesthetic. The muscle activity should start to fade. Stimulation should occur at 0.5 mA but not at or below 0.2 mA.
6. Aspirate for blood prior to and during injection. It is important to ensure that you have not inadvertently entered a vessel. Intra-neural injection can result in transient or permanent injury. Do not continue to inject if the patient complains of pain.

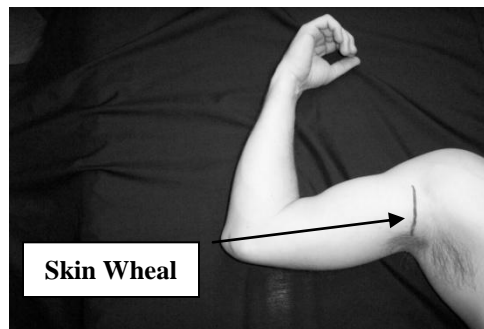
7. Some clinicians will inject all of the local anesthetic in one area. Other clinicians will deposit some local anesthetic at one nerve and then seek others to deposit the rest of the local anesthetic.

Musculocutaneous Block

Regardless of the technique used, it is essential to block the musculocutaneous nerve separately. The musculocutaneous nerve separates from the brachial plexus prior to its entrance into the axilla. The musculocutaneous nerve innervates the biceps and brachialis muscles, providing sensory innervation to the lateral forearm and wrist. Blockade of this nerve can be accomplished by redirecting the needle superiorly and proximally, piercing the belly of the coracobrachialis muscle, and inject 5-10 ml of local anesthetic.

Intercostobrachial and Medial Brachial Cutaneous Nerve Blocks

If a tourniquet is used, it is essential to block the intercostobrachial (T2) and medial brachial nerves (C8-T1). These two nerves are found superficially. Both provide superficial sensation of the medial and posterior portions of the upper arm. A simple “skin wheal” of local anesthetic will reliably block these nerves.



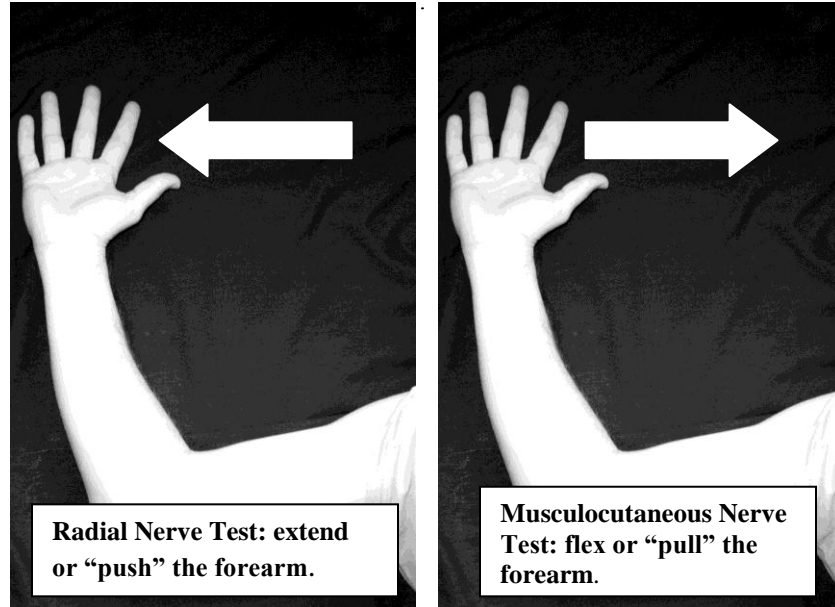
Intercostobrachial and medial brachial cutaneous nerve block

A Simple, Quick, and Easy Test an Axillary Block

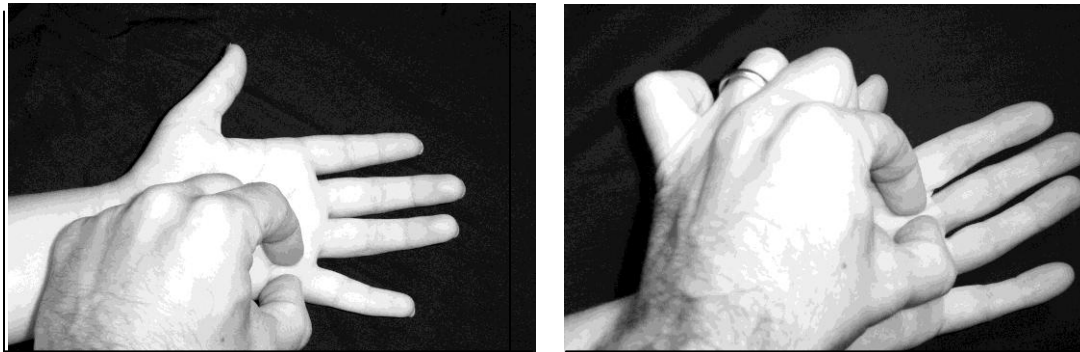
To quickly assess the block, perform the “push-pull-pinch-pinch” test. This test can be done in less than a minute. It can identify “missed” nerves allowing time to formulate an alternative plan of anesthesia (i.e. supplementation or general anesthesia).

- Ask the patient to extend or “push” their forearm against light resistance. This tests the radial nerve.
- Ask the patient to flex or “pull” the arm towards the nose against light resistance. This will test the musculocutaneous nerve.
- Pinch the thenar aspect of the hand (i.e. on the palmar surface of the hand). This will test the median nerve.
- Pinch the hypothenar aspect of the hand (i.e. small finger). This will test the ulnar nerve.

“Push and Pull”



“Pinch, Pinch”



Pinch the ulnar nerve distribution.

Pinch the median nerve distribution.

Local Anesthetics

Lidocaine, mepivacaine, or ropivacaine are commonly used for the axillary approach. Epinephrine will prolong the length of blockade with lidocaine and mepivacaine. Epinephrine is not added to ropivacaine due to its inherent vasoconstrictive properties. An axillary block with lidocaine/mepivacaine will have an onset of 5-15 minutes, an anesthetic duration of 2.5-4 hours, and provide analgesia for 3-6 hours. Ropivacaine will have a longer onset of 20-30 minutes, anesthetic duration of 6-8 hours, and provide analgesia for 8-12 hours. Many clinicians avoid bupivacaine secondary to the risk of cardiac arrest associated with inadvertent intravascular injection. It is important to calculate and not exceed the maximum dose of local anesthetic. The volume of local anesthetic varies from patient to patient depending on age and weight. For example, an adult can have 30-40 ml (smaller volumes if the patient weighs less than 70 kg), and teenagers who weigh 40-60 kg can have 25-30 ml.

Complications

- The incidence of complications is very low
- Intravascular injection is a potentially catastrophic complication. With careful and deliberate aspiration and monitoring, it can be avoided.
- Risk of nerve trauma secondary to eliciting repeated paresthesias’.
- Hematoma and infection are rare complications. Careful preparation of the site with antiseptic will decrease the risk of infection. Holding pressure at the site after penetrating the vessel will reduce the risk of hematoma.

Peripheral Nerve Blocks at the Elbow, Wrist, and Digital Block

Peripheral nerve blocks at the elbow, wrist, or digits are easy to perform and useful in the clinical setting.

Indications

- Supplementing brachial plexus anesthetics that “missed” a nerve
- Postoperative pain relief after a Bier block
- Minor surgical procedures of the hand and fingers
- Closed reduction of the digits
- Analgesia for traumatic injuries of the hand or digits

Advantages & Disadvantages

Advantages include the following:

- Easy to administer
- Low incidence of block failure
- Safe technique when used appropriately
- Rapid onset
- Avoid complications associated with general anesthesia

Disadvantages include the following:

- Must have an intimate knowledge of anatomy
- Patient will have full motor control
- Muscles will not be relaxed
- Cannot use an arm tourniquet due to tourniquet pain

Complications

- Intra-neural injection- never inject if the patient complains of pain/paresthesia or there is resistance to injection.

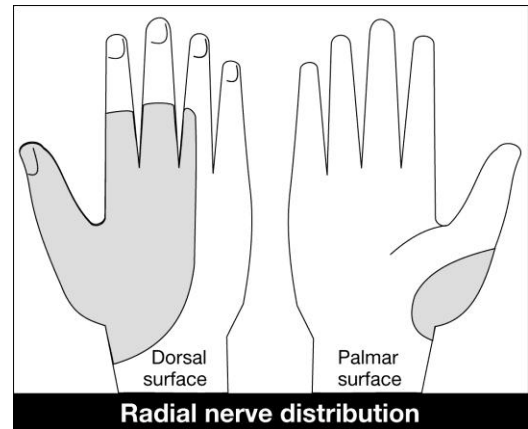
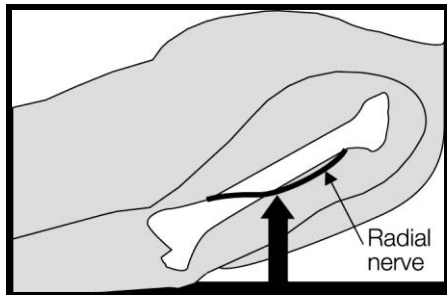
- Intravascular injection- always aspirate before, during, and after injection to ensure a vessel or artery has not been entered.
- Infection- cleanse site with antiseptic, maintain sterility

Peripheral Nerve Blocks at the Elbow and Wrist

When performing brachial plexus anesthesia techniques, there is always the risk that a nerve distribution may be “missed”. If it is not in the surgical area then it is not a major concern. If it is, the ability to supplement the block is essential to a successful anesthetic. In addition, minor surgical procedures may be carried out by blocking individual nerves or a combination of nerves at the elbow and/or wrist. Peripheral nerve blocks require sterile equipment and antiseptic solution. Be careful not to contaminate the area of needle insertion.

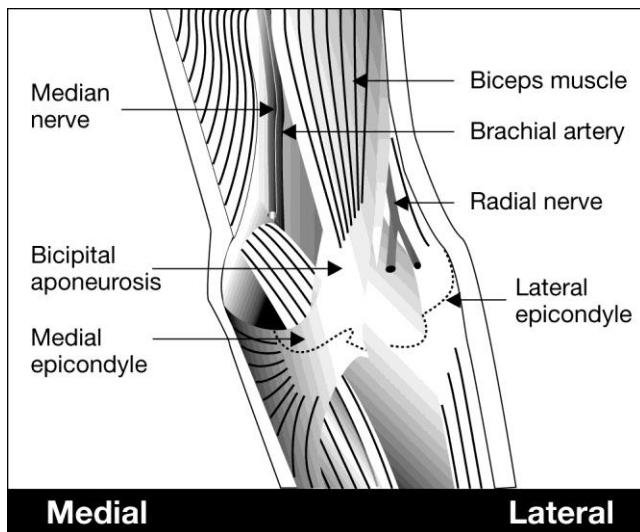
Radial Nerve

The posterior cord of the brachial plexus forms the radial nerve. The radial nerve separates from the brachial plexus sheath, traveling posterior to the humerus, innervating the triceps muscle. The radial nerve then travels to the lateral side of the elbow. Sensory branches, at this point, include the lateral cutaneous nerve of the arm and posterior cutaneous nerve of the forearm. (Refer to the illustration of the cutaneous innervation of the arm.) At the lateral epicondyle of the elbow, the radial nerve divides into superficial and deep branches. The deep branch innervates the postaxial extensor muscles of the forearm. The superficial branch supplies sensation to the dorsal wrist and lateral three and a half fingers.



At the lateral epicondyle of the elbow, the radial nerve divides into superficial and deep branches. The deep branch innervates the postaxial extensor muscles of the forearm. The superficial branch supplies sensation to the dorsal wrist and lateral three and a half fingers.

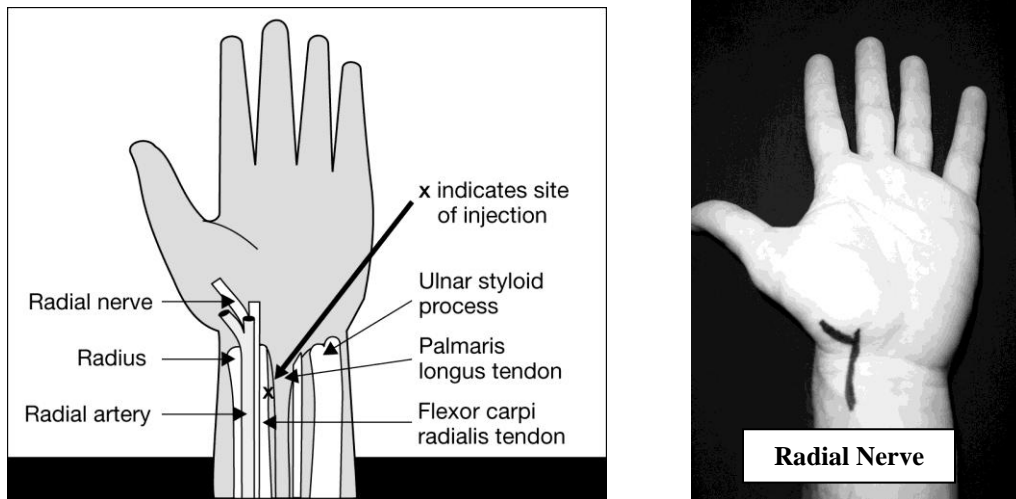
Blockade of the Radial Nerve at the Elbow



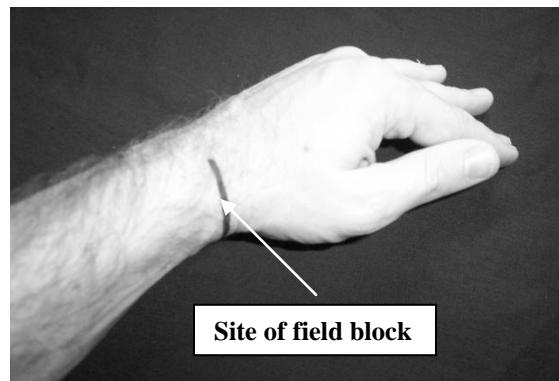
Identify the lateral aspect of the biceps tendon at the crease of the elbow. Insert a 22-27 gauge, 4 cm blunted needle parallel to the forearm. Direct the needle toward the lateral epicondyle. If a paresthesia is encountered, withdraw the needle slightly, and inject 5 ml of local anesthetic. Do not inject if the patient complains of a paresthesia. If no paresthesia is encountered, continue to insert the needle until bone is encountered. Withdraw the needle 1 cm and inject 5 ml of local anesthetic.

Blockade of the Radial Nerve at the Wrist

At the wrist, the radial nerve is located between the radial artery and flexor carpi radialis tendon. The administration of 2-5 ml of local anesthetic, deep to the flexor carpi radialis will block the sensory branches of the radial nerve which innervate the lateral side of the thumb. Proximal to the wrist, dorsal branches of the radial nerve provide sensation to the dorsal aspect of the lateral three and half fingers. This branch can be blocked by placing a superficial field block at the wrist.



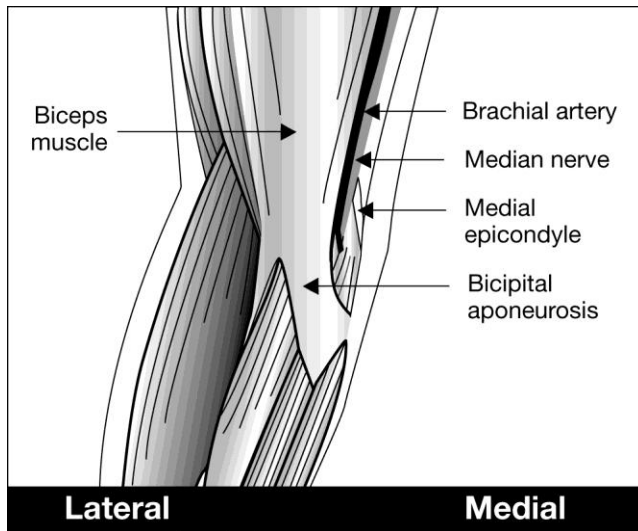
Field Block for the Superficial Radial Branches



Median Nerve

Lateral and medial cords of the brachial plexus contribute to the formation of the median nerve. The median nerve is medial to the brachial artery as it travels down the upper arm. At the elbow, the median nerve is located medial to the brachial artery near the insertion of the biceps tendon. It has several motor branches innervating portions of the wrist and finger flexors. The median nerve at the wrist is located beneath the palmaris longus tendon in the carpal tunnel.

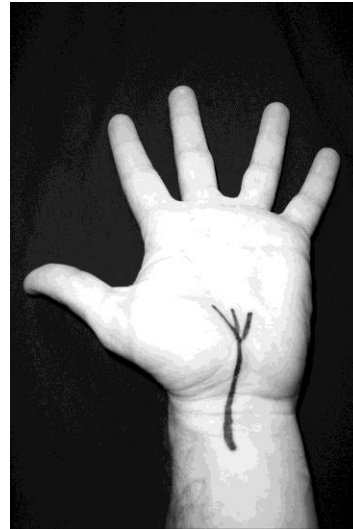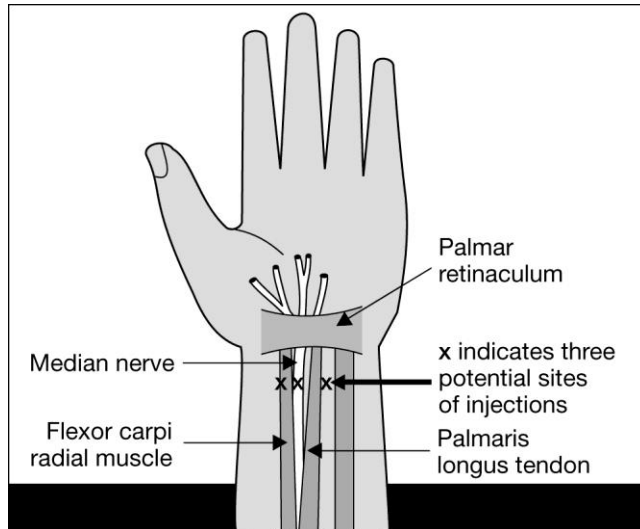
Blockade of the Median Nerve at the Elbow

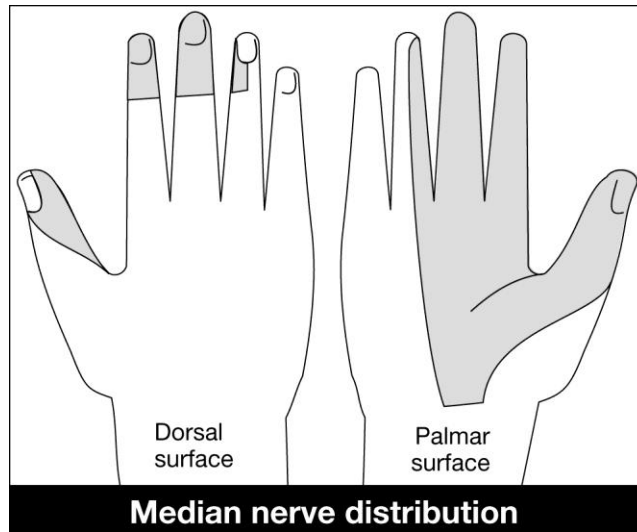


Identify the brachial artery in the antecubital space. It is generally located medially, at the biceps tendon insertion. Insert a 22-27 gauge, 4 cm blunted needle medial to the brachial artery. Direct the needle toward the medial epicondyle. If a paresthesia is encountered, withdraw the needle slightly and inject 3-5 ml of local anesthetic. If a paresthesia is not encountered, continue insertion of the needle until bone is contacted. At this point withdraw the needle 1 cm and inject 3-5 ml of local anesthetic.

Blockade of the Median Nerve at the Wrist

Identify the palmaris longus tendon by asking the patient to flex their wrist against resistance. Insert a 22-27 gauge blunted needle medial and deep to the palmaris longus. Alternatively, injection of local anesthetic into the flexor carpi radialis tendon or between the flexor carpi ulnaris and palmaris longus may carry a lower incidence of nerve trauma while being equally effective. If a paresthesia is encountered, withdraw the needle slightly and inject 3-5 ml of local anesthetic. If no paresthesia is encountered, infiltrate the area with 3-5 ml of local anesthetic.

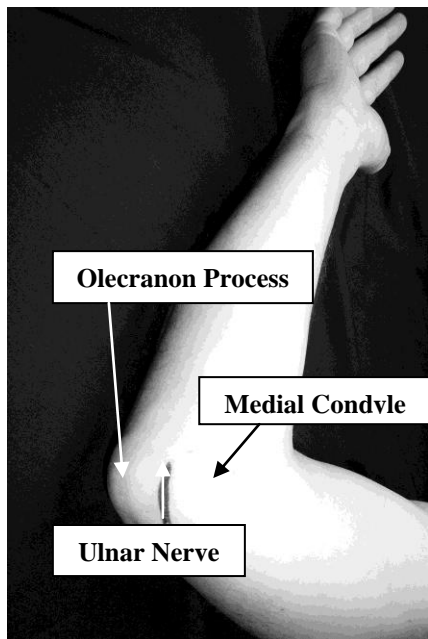




Ulnar Nerve

The medial cord of the brachial plexus contributes to the formation of the ulnar nerve. The ulnar nerve is located medial to the axillary and brachial arteries in the upper arm. At the elbow, the ulnar nerve can be palpated proximal to the medial epicondyle. The ulnar nerve, at the wrist, is located lateral to the flexor carpi ulnaris tendon and medial to the ulnar artery.

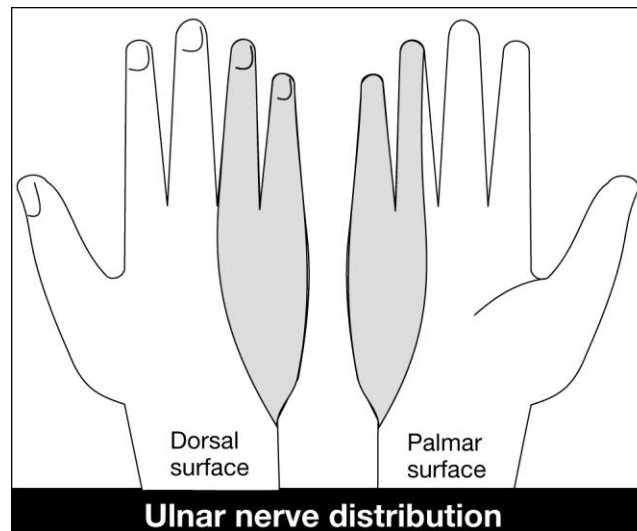
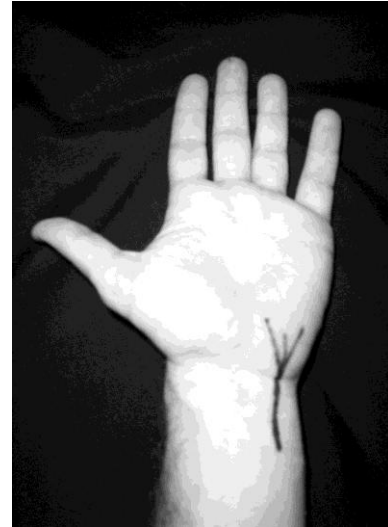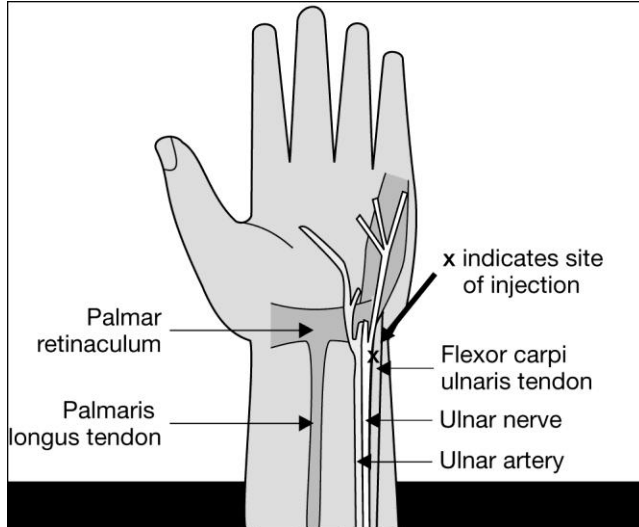
Blockade of the Ulnar Nerve at the Elbow



To anesthetize the ulnar nerve at the elbow, have the patient flex their arm 90 degrees. Identify the olecranon process and the medial condyle. The ulnar nerve can be palpated between these two structures. Insert a 22-27 gauge blunted needle slowly in this space. The ulnar nerve will be superficial. If a paresthesia is obtained, withdraw the needle slightly and inject 3-5 ml of local anesthetic. If no paresthesia, then superficially infiltrate the area with local anesthetic.

Blockade of the Ulnar Nerve at the Wrist


Locate the pulsation of the ulnar artery on the palmar surface of the wrist. Insert a 22-27 gauge blunted needle on the medial side of the arterial pulsation. The ulnar nerve is superficial. If a paresthesia is obtained, pull back slightly and inject 3-5 ml of local anesthetic. If there is not a paresthesia, infiltrate the area with local anesthetic.



Digital Nerve Blocks

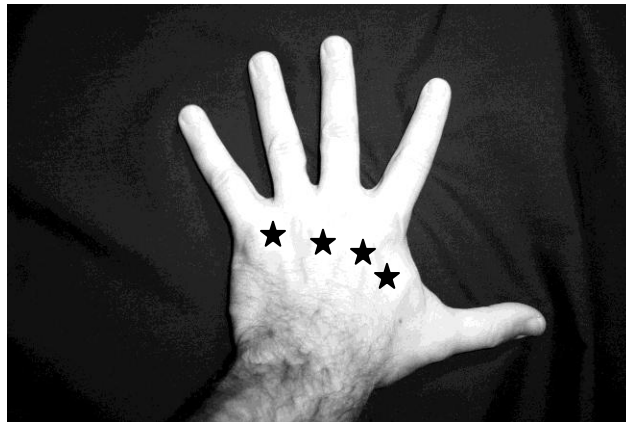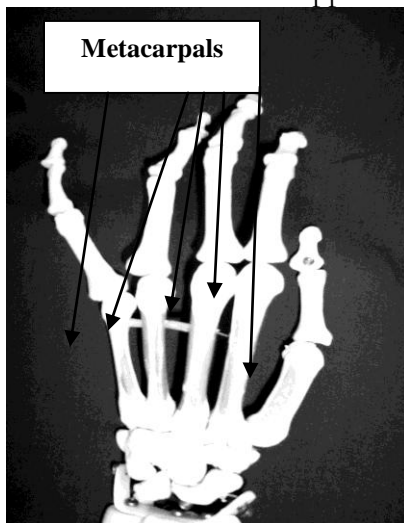
Each digit has two dorsal and two palmar branches of the digital nerve. Digital blocks are easy to administer and quite effective. There are some important considerations.

1. Never use epinephrine containing local anesthetics. Epinephrine can result in vasoconstriction, ischemia, and if severe loss of the digit.
2. Use the least amount of local anesthetic possible. Never administer more than 4 ml of total volume per digit. A volume exceeding this amount can result in a "tourniquet" effect, decreasing blood flow resulting in ischemia.



Metacarpal Block

A metacarpal block is an alternative to a digital nerve block. Some hand surgeons feel that it is a safer alternative to a digital nerve block due to concerns about the tourniquet effect exerted by local anesthetic volume. Never use epinephrine containing solutions. This can result in ischemia to the digit. A small skin wheal should be placed on the dorsum of the hand. Advance the needle while injecting local anesthetic parallel to the metacarpal bone. Do not go through the surface of the palm. The nerve is closer to the palmar surface than the dorsum. Most of the local anesthetic should be deposited in this region. A total of 3-5 ml of local anesthetic can be deposited. The same procedure should occur on the opposite side of the metacarpal.



References

Burkard J, Lee Olson R., Vacchiano CA. Regional Anesthesia. In Nurse Anesthesia 3rd edition. Nagelhout, JJ & Zaglaniczny KL ed. Pages 977-1030.

Morgan, G.E. & Mikhail, M. (2006). Peripheral nerve blocks. In G.E. Morgan et al *Clinical Anesthesiology*, 4th edition. New York: Lange Medical Books.

Wedel, D.J. & Horlocker, T.T. Nerve blocks. In Miller's Anesthesia 6th edition. Miller, RD ed. Pages 1685-1715. Elsevier, Philadelphia, Penn. 2005.

Wedel, D.J. & Horlocker, T.T. (2008). Peripheral nerve blocks. In D.E. Longnecker et al (eds) *Anesthesiology*. New York: McGraw-Hill Medical.