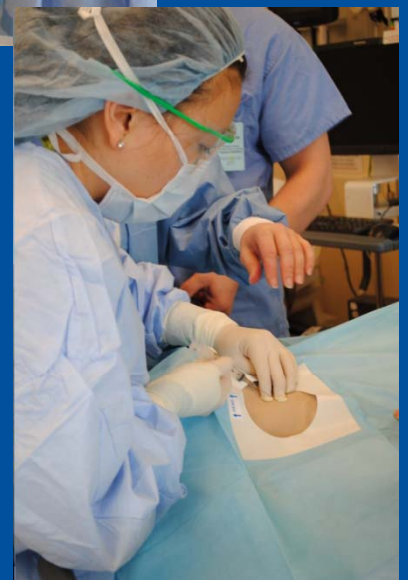
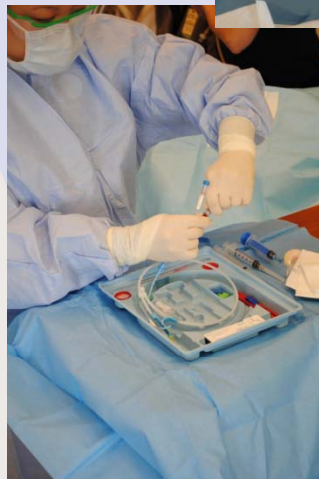
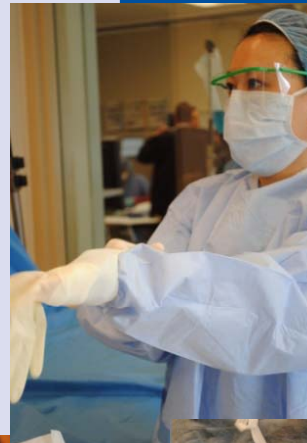
Volume 9 Number 3 Fall 2010

# *The International Student Journal of Nurse Anesthesia*

## **TOPICS IN THIS ISSUE**

Septic Shock & Methamphetamine Use  
Local Anesthesia for Knee Arthroscopy  
Congenital Heart Malformations  
Respiratory Distress Syndrome  
Post-dural Puncture Headache  
Peripartum Cardiomyopathy  
Maxillomandibular Fixation  
Trigemino-cardiac Reflex  
Hypoglossal Nerve Injury  
Osteogenesis Imperfecta  
Mitochondrial Myopathy  
Pulmonary Embolism  
Sebastian Syndrome  
Felty's Syndrome  
Placenta Accreta  
Cricoid Pressure



**INTERNATIONAL STUDENT JOURNAL OF NURSE ANESTHESIA**  
**Vol. 9 No. 3, Fall 2010**

**Editor**

Vicki C. Coopmans, CRNA, PhD

**Associate Editor**

Julie A. Pearson, CRNA, PhD

**Editorial Board**

Carrie C. Bowman Dalley, CRNA, MS	Georgetown University
Janet A. Dewan, CRNA, MS	Northeastern University
Rhonda Gee, CRNA, DNSc	Decatur Memorial Hospital /Bradley University
Michele Gold, CRNA, PhD	University of Southern California
Robert Hawkins, CRNA, MS, MBA, DNP	Naval School of Health Sciences
Donna Jasinski, CRNA, DNSc	Georgetown University
Russell Lynn, CRNA, MSN	University of Pennsylvania
Maria Magro, CRNA, MS, MSN	University of Pennsylvania
MAJ Denise McFarland, CRNA, MSN, AN	U.S Army Graduate Program in Anesthesia Nursing, Tripler Army Medical Center
Greg Nezat, CRNA, PhD	Naval School of Health Sciences
Teresa Norris, CRNA, EdD	University of Southern California
Christopher Oudekerk, CRNA, DNP	Naval Medical Center, Portsmouth
Michael Rieker, CRNA, DNP	Wake Forest University Baptist Medical Center, University of North Carolina at Greensboro
LCDR Dennis Spence, CRNA, PhD, NC, USN	Naval School of Health Sciences
Edward Waters, CRNA, MN	California State University - Fullerton, Kaiser Permanente School of Anesthesia
Lori Ann Winner, CRNA, MSN	University of Pennsylvania
Kathleen R. Wren, CRNA, PhD	Florida Hospital College of Health Sciences

**Contributing Editors For This Issue**

Darla A. Adams, CRNA, PhD	University of North Dakota
Kevin C. Buettner, CRNA, MS	University of North Dakota
Gary Clark, CRNA, EdD	Webster Univeristy
Sass M. Elisha, CRNA, EdD	California State University - Fullerton, Kaiser Permanente School of Anesthesia
Joseph Joyce, CRNA, BS	Wake Forest University Baptist Medical Center, University of North Carolina at Greensboro
Mike Sadler, CRNA, MSNA	Texas Christian University
Denise Tola, CRNA, MSN	Georgetown University

## Reviewers For This Issue

Matthew Bishop, CRNA, MSN	Tripler Army Medical Center
Courtney Brown, CRNA, MSN	Wake Forest University Baptist Medical Center, University of North Carolina at Greensboro
Kevin Buss, CRNA, MS	Uniformed Services University Graduate School of Nursing
Connie Calvin, CRNA, PhD	Northeastern University
Marjorie A. Geisz-Everson, CRNA, PhD	Louisiana State University Health Sciences Center
Stephanie Fan, CRNA, MSN	Washington University School of Medicine; St. Louis, MO
Michael Neill, CRNA, MSN	Tripler Army Medical Center
Johanna Newman, CRNA, MS	Florida Hospital College of Health Sciences
Ilene Ottmer, CRNA, MSN	Washington University School of Medicine; St. Louis, MO
Jesse Rivera, CRNA, MSN	Naval Hospital; Camp Pendelton, CA
CPT Priscella Shaw, CRNA, MSN	Tripler Army Medical Center, HI
Lori Stone, CRNA, MSN	Decatur Memorial Hospital /Bradley University
Denise Tola, CRNA, MSN	Georgetown University

*The **opinions** contained in this journal are those of the student and do not necessarily represent the opinions of the program or the University*

***Disclaimer for all articles authored by military personnel:** The views expressed in this journal are those of the authors and do not necessarily reflect the official policy or position of their respective Military Department, Department of Defense, Uniformed Services University of the Health Sciences nor the U.S. Government. The work was prepared as part of the official duties of the military service member. Title 17 U.S.C. 105 provides that 'Copyright protection under this title is not available for any work of the United States Government'. Title 17 U.S.C. 101 defines a United States Government work as a work prepared by a military service member or employee of the United States Government as part of that person's official duties.*

Front Cover:

Mimi Brown, RN, BSN, a graduate student enrolled in the Goldfarb School of Nursing at Barnes-Jewish College Nurse Anesthesia Program, practices central line insertion in the College's Clinical Simulation Institute. (Photograph by Chris Tobnick, BA).

The Guide for Authors: can be found at [www.aana.com](http://www.aana.com) by following this path:

Professional Development > Nurse Anesthesia Education > For Students (Scroll to the bottom of the page) > Guide for Authors

Or, use this direct link: <http://www.aana.com/studentjournal.aspx>

## Table of Contents

### *Case Reports*

<b>Cricoid Pressure During Rapid Sequence Induction .....</b>	<b>5</b>
Melissa J. Davey, Northeastern University	
<b>Anesthesia Considerations for Placenta Accreta .....</b>	<b>8</b>
Melissa VanMatre, University of North Dakota	
<b>Hypoglossal Nerve Injury Following Airway Manipulation.....</b>	<b>12</b>
Eva Marie Jorden, Texas Christian University	
<b>Anesthesia Management for Sebastian Syndrome.....</b>	<b>15</b>
Jennifer Henjum, University of North Dakota	
<b>Septic Shock and Habitual Methamphetamine Use .....</b>	<b>17</b>
Lee Ranalli, Kaiser Permanente School of Anesthesia	
<b>Suspected Trigemino-Cardiac Reflex During Pediatric Tonsillectomy.....</b>	<b>21</b>
Jason Goff, Uniformed Services University of the Health Sciences	
<b>Treatment of Post-Dural Puncture Headache with Ketoralac .....</b>	<b>24</b>
Chad Moore, Uniformed Services University of the Health Sciences	
<b>Intraoperative Pulmonary Embolism .....</b>	<b>27</b>
Laurel Schooler, University of Southern California	
<b>Anesthetic Management of Felty's Syndrome.....</b>	<b>30</b>
Felicity Rensberger, University of Southern California	
<b>Anesthesia for Maxillomandibular Fixation .....</b>	<b>34</b>
Christopher D. Kyle, Georgetown University	
<b>Acute Respiratory Distress Syndrome in the Cardiac Patient .....</b>	<b>37</b>
Lyndsay A. Bikul, Kaiser Permanente School of Anesthesia	
<b>Undiagnosed Peripartum Cardiomyopathy .....</b>	<b>41</b>
Ashleah Pope, University of Southern California	
<b>Management of the Pediatric Patient with Osteogenesis Imperfecta .....</b>	<b>44</b>
Benjamin Lindsey, University of Southern California	
<b>Mitochondrial Myopathy: Designing an Anesthetic Plan .....</b>	<b>47</b>
Kathryn W. Phares, Wake Forest University Baptist Medical Center, University of North Carolina at Greensboro	

**Local Anesthesia and Sedation for Knee Arthroscopy.....50**  
Johnny K. Cheng, University of Southern California

**The Patient with Complex Congenital Heart Malformations.....53**  
Crystal M. Alber, Webster University

## Cricoid Pressure During Rapid Sequence Induction

Melissa J. Davey, BSN  
Northeastern University

**Keywords:** cricoid pressure, rapid sequence induction, Sellick's maneuver, BURP, bi-manual laryngoscopy

Cricoid pressure, also known as Sellick's maneuver, was first described in 1961.<sup>1</sup> The two main purposes for applying cricoid pressure are prevention of gastric regurgitation during induction of anesthesia and prevention of gastric insufflation during positive pressure ventilation.<sup>2</sup> Sellick described his maneuver as "occlusion of the upper esophagus by backward pressure on the cricoid ring against the bodies of cervical vertebrae to prevent gastric contents from reaching the pharynx."<sup>1</sup> This technique quickly gained acceptance as an adjunct for rapid sequence intubation. However, the application of cricoid pressure does not always prevent gastric regurgitation during the induction of anesthesia, and its utility has been questioned.<sup>3</sup>

### Case Report

A 55 year old, 47 kg, 63 inch female with a diagnosis of right breast cancer presented for wire-localized lumpectomy and sentinel node mapping and biopsy. Past medical history consisted of a hiatal hernia, gastroesophageal reflux disease (GERD), Shatzki ring, osteoporosis, and depression. Home medications consisted of lorazepam, multivitamin, magnesium, calcium, vitamin D, blue-green algae supplement, and enterozyme. Airway exam resulted in a Mallampati class 2 score. Thyromental distance was assessed as two fingerbreadths and the patient had a small mouth opening with large frontal incisors.

Preoperatively, the patient stated that she was easily nauseated and had a history of motion sickness. A scopolamine patch 1.5 mg was placed behind the left ear. An 18-gauge peripheral intravenous catheter was placed in the left forearm. Midazolam 2 milligrams (mg) was administered intravenously (IV) in divided doses followed by metoclopramide 10 mg IV. The patient entered the operating room and a pulse oximeter, non-invasive blood pressure cuff, and a 5-lead electrocardiogram were applied. She was preoxygenated via a face mask. Intravenous induction followed with lidocaine 80 mg, propofol 200 mg, fentanyl 50 micrograms (mcg), and succinylcholine 90 mg. Cricoid pressure was lightly applied by the surgeon while the patient was awake and then firmer pressure applied upon loss of consciousness. A rapid sequence intubation followed. A direct laryngoscopy was performed with one attempt using a Macintosh 3 blade. Initially, a grade 3 Cormack and Lehane view was visualized by the laryngoscopist. A modified backward-upward-rightward pressure (BURP) maneuver was then applied improving the view of the laryngoscopist to grade 2. A bougie was requested. Bimanual laryngoscopy was performed by the anesthetist which optimized the laryngeal view to a grade 1. The laryngoscopist provided instruction to the surgeon to assist with laryngeal manipulation and the trachea was intubated successfully with a 6.5 oral cuffed endotracheal tube. The endotracheal tube was taped securely at 21 centimeters (cm) positioned at the teeth. An additional 60 mg of propofol and 75 mcg of fentanyl were administered intravenously throughout the case, each in divided doses.

Dexamethasone 6 mg IV was administered after induction of anesthesia and ondansetron 4 mg IV administered 30 minutes prior to completion of the procedure. Neuromuscular blockade was achieved with cis-atricurium 6 mg and antagonized with neostigmine 3 mg administered concomitantly with glycopyrrolate 0.6 mg upon completion of the procedure. Anesthesia was maintained with 1.5% end-tidal sevoflurane. A bispectral index monitor and nerve stimulator were used. The patient received two liters of lactated ringers intravenously. At the end of the procedure, the patient was awake and responsive to verbal commands, breathing spontaneously, and maintaining tidal volumes between 5 to 10 L/min. The patient demonstrated a sustained head lift, and airway reflexes were present. The trachea was extubated without difficulty. The patient was able to move herself onto the stretcher with minimal assistance and was transferred to the recovery room on 6 L of oxygen administered by face mask.

## Discussion

Cricoid pressure, originally described by Sellick in 1961<sup>1</sup>, is used to prevent passive regurgitation and possible aspiration during induction of anesthesia. It is usually reserved for patients with an increased risk of aspiration when rapid sequence intubation is indicated. The technique consists of exerting downward pressure with the forefinger while preventing lateral displacement of the cricoid ring by the thumb and middle finger.<sup>4</sup> There are conflicting data regarding the anatomical relationship between the esophagus and cricoid cartilage. Theoretically, the esophagus lies posteriorly to the cricoid ring and the application of downward pressure on the cricoid cartilage as described should cause compression of the esophagus

between the cricoid cartilage and cervical spine. This is thought to cause occlusion of the esophageal lumen, thus preventing regurgitation of gastric contents.<sup>5</sup> In an observational study by Smith et al. (2003) using magnetic resonance imaging, the esophagus was lateral in more than 50% of the sample in the absence of cricoid pressure. Furthermore, Smith's group found that the esophagus was displaced laterally in more than 90% of the sample upon application of cricoid pressure.<sup>5</sup> In this study, the head was placed in a neutral position, which could possibly allow the esophagus to be more mobile, as opposed to the head being fully extended when Sellick first described the use of cricoid pressure. However, the head is rarely placed in a fully extended position, but rather in a neutral or sniffing position to optimize the visualization of the larynx. Therefore, the findings of Smith et al. may be more generalizable in the clinical setting. In an opposing study by Rice et al. (2009) using magnetic resonance imaging, the head was placed in sniffing, neutral, and extended positions. The origin of the esophagus is found to be inferior to the level of the cricoid cartilage.<sup>6</sup> The lateral displacement of the esophagus still occurs, however, the location and movement of the esophagus is irrelevant to the effectiveness of Sellick's maneuver in the prevention of gastric regurgitation. Rice et al. state that it is the occlusion of the hypopharynx with the application of cricoid pressure that is essential to the prevention of regurgitation and aspiration.<sup>6</sup>

Manipulation of the external anatomy of the cricoid and thyroid cartilages is frequently used to aid in the optimization of the laryngeal view. The three commonly used techniques include the Sellick maneuver, involving cricoid pressure, backward-upward-rightward pressure (BURP), and

bimanual laryngeal manipulation. Studies have indicated that some of these commonly used techniques may actually worsen the glottic view.<sup>7-10</sup>

BURP was first introduced in 1993 by Knill.<sup>7</sup> The BURP technique involves direction and pressure applied to the thyroid cartilage by an assistant to improve glottic view by the laryngoscopist.<sup>7</sup> The efficacy of this technique was supported by a study conducted by Takahata et al. in which an improvement in glottic view was seen in 630 cases.<sup>8</sup> Snider et al. conducted a study which combined BURP and Sellick's maneuvers in an attempt to improve the glottic view during a rapid sequence induction of anesthesia, while providing protection against passive gastric regurgitation. The results of this study indicated that a modified BURP maneuver worsened the laryngeal view in 30% of the cases and was of no benefit during rapid sequence induction.<sup>9</sup>

Bimanual laryngoscopy involves manipulation of the thyroid cartilage performed by the laryngoscopist with concurrent direct observation of the larynx. After the view is optimized, the laryngeal manipulation is delegated to an assistant, allowing the laryngoscopist's right hand to place the endotracheal tube.<sup>10</sup> Levitan et al. conducted a randomized trial comparing cricoid pressure, BURP, and bimanual laryngoscopy. The results of the study indicated that bimanual laryngoscopy is more effective at improving laryngeal view than BURP or cricoid pressure. The study also indicated that the use of BURP and cricoid pressure frequently worsen laryngoscopy view.<sup>10</sup>

The efficacy of applying cricoid pressure during a rapid sequence induction in patients at increased risk for gastric regurgitation and

aspiration remains controversial. The amount of pressure applied to the cricoid cartilage is universally accepted as 10 newtons (N) in an awake patient followed by an exerted pressure of 30 to 40 N upon loss of consciousness. Multiple studies have indicated that a knowledge deficit exists among assistants providing the necessary amount of pressure to the cricoid cartilage, as well as the appropriate location of anatomical structures. In a non-experimental, correlational, descriptive study, Beavers et al. provided a formalized training program to improve knowledge and skills in medical personnel assisting with the application of cricoid pressure. The study demonstrated that the participants were unable to retain their knowledge and skills after eight months.<sup>11</sup>

Despite the controversy surrounding the use of cricoid pressure during a rapid sequence induction, it is still regarded as a standard of care. In 1991, a judge in the United Kingdom ruled against an anesthetist for failing to provide cricoid pressure to a patient with an irreducible hernia who regurgitated and aspirated.<sup>12</sup> In a recent editorial by Lerman, he states that "the legal community exploits its omission from the anesthetic record as evidence of a practice below the 'accepted' standards" despite having a Grade D recommendation".<sup>3,13</sup> In addition to the application of cricoid pressure during a rapid sequence induction, other measures should be considered in reducing the risk of regurgitation and aspiration, such as minimizing preoperative intake, pharmacologically increasing gastric emptying, and reducing gastric volume and acidity.<sup>4</sup> In the case described, Sellick's maneuver was applied as part of a planned rapid sequence induction and metoclopramide was given pre operatively to hasten gastric emptying. When the laryngeal view proved to be difficult, the



laryngoscopist found that, as supported by the literature, bimanual laryngoscopy afforded a grade one view that was not obtained using cricoid pressure or the BURP maneuver.

## References

1. Sellick BA. Cricoid pressure to control regurgitation of stomach contents during induction of anaesthesia. *Lancet*. 1961;2:404-406.
2. Salem MR, Sellick BA, Elam JO. The historical background of cricoid pressure in anesthesia and resuscitation. *Anesth Analg*. 1974;53:230-232.
3. Neilipovitz DT, Crosby ET. No evidence for decreased incidence of aspiration after rapid sequence induction. *Can J Anaesth*. 2007;54:748-764.
4. Ogunnaike BO, Whitten CW. Gastrointestinal disorders. In Barash PG, Cullen BF, Stoelting RK, Cahalan MK, Stock MC, eds. *Clinical Anesthesia*. 6th ed. Philadelphia:Lippincott Williams & Wilkins; 2009:1223-1224.
5. Smith KJ, Dobranowski J, Yip G, Dauphin A, Choi PT. Cricoid pressure displaces the esophagus: an observational study using magnetic resonance imaging. *Anesthesiology*. 2003;99:60-64.
6. Rice MJ, Mancusco AA, Gibbs C, Morey TE, Gravenstein N, Deitte LA. Cricoid pressure results in compression of the postcricoid hypopharynx: the esophageal position is irrelevant. *Anesth Analg*. 2009;109:1546-1552.
7. Knill RL. Difficult laryngoscopy made easy with a “BURP”. *Can J Anaesth*. 1993;40:279-282.
8. Takahata O, Kubota M, Mamiya K, et al. The efficacy of the “BURP” maneuver during a difficult laryngoscopy. *Anesth Analg*. 1997;84:419-421.
9. Snider DD, Clarke D, Finucane BT. The “BURP” maneuver worsens the glottic view when applied in combination with cricoid pressure. *Can J Anaesth*. 2005;52:100-104.
10. Levitan RM, Kinkle WC, Levin WJ, Everett WW. Laryngeal view during laryngoscopy: a randomized trial comparing cricoid pressure, backward-upward-rightward pressure, and bimanual laryngoscopy. *Ann Emerg Med*. 2006;47:548-555.
11. Beavers RA, Moos DD, Cuddeford JD. Analysis of the application of cricoid pressure: implications for the clinician. *J Perianesth Nurs*. 2009;24:92-102.
12. Vanner R. Cricoid pressure. *Int J Obstet Anesth*. 2009;18:106-110.
13. Lerman J. On cricoid pressure: “may the force be with you”. *Anesth Analg*. 2009;109:1363-1366.

**Mentor:** Janet A Dewan, CRNA, MS

## Anesthesia Considerations for Placenta Accreta

Melissa VanMatre, MS  
University of North Dakota

**Keywords:** placenta accreta, placenta previa, maternal hemorrhage, anesthesia

Placenta accreta, a relatively rare condition, is increasing in incidence as a result of more

frequent cesarean section deliveries.<sup>1</sup> Statistically it occurs in 1 out of every 533 deliveries.<sup>2</sup> Parturients are at an 11% risk of this condition when associated with placenta previa and prior cesarean delivery.<sup>2</sup>

According to Gabbe et al, the “risk rises to 67% when placenta previa occurs with a history of four or more cesarean deliveries”.<sup>2</sup> Massive hemorrhage, disseminated intravascular coagulation, urinary and renal complications, and respiratory distress syndrome are some of the major morbidities resulting from placenta accreta.<sup>3</sup>

## Case Report

A 25 year old gravida 4 parity 3 at 37 weeks gestation presented for cesarean section due to diagnosed placenta previa. Patient weighed 80kg and measured 58in.. She had no significant health history with previous anesthesia for tonsillectomy and three prior cesarean sections with no anesthesia complications.

Preoperative laboratory values included; hemoglobin (Hgb) 9.2 g/dl, hematocrit (Hct) 27.2%, and platelet count 222 x1000/mm<sup>3</sup>.

An ultrasound completed 8 days prior indicated complete placenta previa. The patient was typed and crossed for 2 units packed red blood cells (PRBCs).

The anesthetic plan was cesarean section under spinal anesthetic. The patient presented to the operating room in stable condition with a 20 gauge (g) peripheral IV and an additional 16g PIV was inserted. A spinal block consisting of 0.75% bupivacaine 1.6 ml, fentanyl 25 mcg, and duramorph 0.15 mg was administered without difficulty and the patient was medicated with phenylephrine 100 mcg for a 20% drop in baseline blood pressure. The baby was delivered without incident with an incision to delivery time of 8 min. Pitocin 20 units was injected into the infusing IV fluids following cord clamping.

Significant blood loss was then noted in the suction canister. The patient was medicated

with methergine 0.2 mg IM, one unit of specific PRBC, and hespan 500 ml. Despite treatment, rapid blood loss continued and the patient’s BP subsequently dropped to 60/29, HR 115. Ephedrine and phenylephrine were administered IV and a phenylephrine infusion was initiated as the patient began to lose consciousness. At this time, the surgeon determined an emergent hysterectomy would be necessary for inability to control intraoperative hemorrhaging.

Conversion to a general anesthetic was initiated with etomidate 14 mg and succinylcholine 100 mg. A second unit of type specific PRBC was administered and a unit of O negative PRBCs was initiated due to continued hemorrhage. A diagnosis of placenta percreta was made at this time. A central and arterial line were placed under ultrasound guidance. Four units fresh frozen plasma (FFP) and 6 units of platelets were administered. Calcium chloride 500 mg IV was administered after completion of 7 units PRBCs. Full body forced air warmers and fluid warmers were instituted for a patient temperature of 34.4 °C. Following the 8<sup>th</sup> and final unit PRBCs, laboratory results were as follows: Hgb 10.1g/dl, Hct 29%, platelet count 83 x1000/mm<sup>3</sup>, PT 14.9 s, and PTT 32 s. Estimated blood loss totaled 5,000 ml. The endotracheal tube was removed after the patient was awake. She was then transferred to the post anesthesia care unit with stable vital signs.

## Discussion

Placenta accreta is an abnormal formation of the placenta that can present in three forms. Placenta accreta vera is the development of the placenta on the surface of the uterine muscle.

Placenta increta occurs when the placenta invades the muscle wall of the uterus and placenta percreta involves complete invasion of the placenta through the muscle wall of the uterus.<sup>4</sup> These abnormal placental-uterine developments create a problem during delivery as the placenta fails to separate causing massive bleeding and a lack of hemostasis.<sup>1,3</sup> Each can cause fatal hemorrhage during cesarean delivery creating complicated management for the anesthesia practitioner.<sup>5</sup> Major risk factors include one or more previous cesarean deliveries and history of prior placenta previa or existing previa.<sup>1</sup> The mortality for parturients with placenta accreta is 7% with morbidity found to be as high as 59% in a 2009 study.<sup>1,6</sup> This patient presented with a history of three previous cesarean sections and diagnosed placenta previa, two of the most significant risk factors for placenta accreta.<sup>2</sup>

Early detection and diagnosis of placenta accreta is important to allow for planned surgical intervention. Ultrasonography and magnetic resonance imaging can be utilized to detect irregularities in the placenta leading to a diagnosis or suspicion of placenta accreta.<sup>1,3</sup> Weinger et al, however, reported that “diagnosis cannot be established definitively with ultrasound, thus the diagnosis can be made only at surgery”.<sup>6</sup> Prior diagnosis permits the surgical team, including anesthesia, to be prepared for the associated complications of abnormal placental implantation and prevent maternal mortality.

Eller et al. found that maternal morbidities are reduced in cases of suspected and identified placenta accreta by allowing for preoperative ureteric stenting and scheduled cesarean hysterectomy without attempting to remove the placenta.<sup>6</sup> Attempts to remove the placenta may lead to uncontrollable

hemorrhage and emergent hysterectomy.<sup>6</sup> A planned cesarean hysterectomy is often the recommended treatment for parturients with placenta accreta however conservative management strategies, such as, surgical uterine devascularisation of an intact placenta, embolization of uterine vessels, placement of compression sutures in the uterus and over sewing the placental vascular bed have also been identified as a way to maintain fertility.<sup>6</sup> Oyelese et al recommends surgical treatment consisting of a scheduled cesarean hysterectomy at 36-37 weeks gestation to avoid major intraoperative blood loss and/or a later non-controlled emergency delivery.<sup>3</sup>

Regardless of the surgical intervention planned, it is vital that the anesthesia practitioner be prepared to prevent and treat all of the complications associated with placenta accreta. Ideally the patient should have preoperative counseling regarding the complications associated with this condition, stressing hysterectomy and the likely need for transfusion therapy.<sup>3</sup>

Anesthetic choice will depend on the stability of the patient and hospital protocols. Anesthesia protocols often require all cases of suspected placenta accreta patients undergoing cesarean delivery be given general anesthesia via rapid sequence induction, although regional anesthesia may be used for lower risk non-emergent cases.<sup>7</sup> According to Oyelese et al regional anesthesia can be a safe anesthetic choice in the management of placenta accreta.<sup>3</sup> However, general anesthesia provides more hemodynamic control without the sympathetic blockade of a spinal anesthetic and airway control during massive intraoperative bleeding. In this case study a regional anesthetic was converted to a general anesthetic due to uncontrollable

hemorrhage leading to hemodynamic instability and ensuing loss of consciousness.

Preparation to replace blood loss quickly should be considered regardless of anesthetic technique chosen. Two large bore IVs should be placed to allow for rapid fluid resuscitation and timely blood transfusion therapy.<sup>2,5,7</sup> A central line should also be considered for a reliable large IV access and for central venous pressure monitoring.<sup>5,8</sup> For accurate BP measurement and access for laboratory draws, an arterial line should be inserted preoperatively.<sup>8</sup> Immediate availability of blood products should be confirmed with the hematology department and OR staff.<sup>8</sup> Two to four units of cross matched PRBCs should be accessible and ready for transfusion prior to surgery.<sup>5,7</sup> Cell saver use and acute normovolemic hemodilution should also be considered to reduce the need for transfusion.<sup>5</sup> These patients are at risk for developing coagulopathies associated with massive PRBC transfusions and replacement of coagulation factors is an important concern.<sup>3</sup> Weiniger et al. stress the need to prepare all patients with placenta accreta for maternal hemorrhage and recommend an anesthesia protocol requiring 2 units of FFP be readily available.

Preparation for complications of any procedure is an important task for the anesthesia practitioner. In this case placenta accreta was not diagnosed prior to cesarean section. However patient risk factors associated with placenta accreta should have lead the anesthesia team to identify and

prepare for possible intraoperative complications.

## References

1. Warshak CR, Ramos GA, Ramez E, et al. Effect of Predelivery Diagnosis in 99 Consecutive Cases of Placenta Accreta. *Obstet Gynecol.* 2010;115:65-69.
2. Gabbe SG, Niebyl JR, Simpson JL, et al. *Obstetrics: Normal and Problem Pregnancies.* 5<sup>th</sup> ed. Philadelphia, Pennsylvania: Churchill Livingstone Elsevier;2007:464-465.
3. Oyelese Y, Smulian JC. Placenta Previa, Placenta Accreta, and Vasa Previa. *Obstet Gynecol.* 2006;107(4):927-941.
4. Nagelhout JJ, Plaus KL. *Handbook of Nurse Anesthesia.* 4<sup>th</sup> ed. St Louis, Missouri: Saunders Elsevier Inc; 2010:439.
5. Kuczkowski KM. Anesthesia for the repeat cesarean section in the parturient with abnormal placentation: What does an obstetrician need to know. *Arch Gynecol Obstet.* 2006; 273:319-321.
6. Eller AG, Porter TF, Soisson P, et al. Optimal management strategies for placenta accreta. *BJOG.* 2009;116:648-654.
7. Weiniger CF, Elram T, Ginosar Y, et al. Anaesthetic management of placenta accreta: use of a pre-operative high and low suspicion classification. *Anaesthesia.* 2005;60:1079-1084.
8. James DK, Steer PJ, Weiner CP, et al. *High-Risk Pregnancy.* 3<sup>rd</sup> ed. Philadelphia, Pennsylvania: Saunders Elsevier;2005:1563-1565.

**Mentor:** Darla J. Adams, CRNA, PhD

## Hypoglossal Nerve Injury Following Airway Manipulation

Eva Marie Jorden, BSN  
Texas Christian University

**Keywords:** Hypoglossal nerve palsy, airway complication, twelfth cranial nerve, intubation, bronchoscopy

Unilateral hypoglossal nerve injury is a rare complication that can occur from airway manipulation during anesthesia and little research exists to explain the phenomenon. Many devices used during airway manipulation have been associated with injury, including laryngoscopy and intubation, laryngeal mask airways, and bronchoscopy procedures.<sup>1,2</sup> Clinical manifestations include dysphagia and dysarthria, predisposing the patient to the risk for aspiration. Anesthesia practitioners should be aware of this rare complication and be able to recognize it in the postoperative period. Early recognition can improve patient safety, alleviate patient anxiety, and accelerate diagnosis to better guide therapeutic interventions.

### Case Report

A 70 year old, 82 kg female was admitted to outpatient surgery for bronchoscopy with use of argon plasma photocoagulation for ablation of a tumor causing a left lower lobe airway obstruction. The patient was assigned an ASA II physical classification for a history that included renal cell carcinoma with metastasis to the lungs and status post radiation and chemotherapy. Current medications included dexamethasone and omeprazole. Physical examination findings were unremarkable; airway examination showed a Mallampati 1, a thyromental distance greater than 3 fingerbreaths, and full neck range of motion. The patient was placed supine preoxygenated with 100%

oxygen. A five-lead EKG, a pulse oximeter, and a non-invasive blood pressure cuff were attached to the patient.

The patient was induced with fentanyl, lidocaine, propofol and rocuronium intravenously. Mask ventilation was adequate throughout induction. Muscle relaxation was confirmed by zero out of four twitches with a peripheral nerve stimulator applied to the facial nerve. The student registered nurse anesthetist (SRNA) performed laryngoscopy with a Macintosh 3 blade. The SRNA did not attempt intubation due to inadequate view of the glottis. The certified registered nurse anesthetist (CRNA) performed laryngoscopy with Macintosh 3 blade, applied manual pressure to the cricoid cartilage and inserted an 8.0 endotracheal tube into the trachea. No end tidal CO<sub>2</sub> was noted and no breath sounds auscultated. The endotracheal tube was removed and the patient was mask ventilated with 100% oxygen. The CRNA performed a second laryngoscopy with a Miller 2 blade, visualized the inferior portion of the vocal cords and intubated the trachea with an 8.0 endotracheal tube. The cuff was inflated with six ml of air and end tidal CO<sub>2</sub> and bilateral breath sounds were noted. The endotracheal tube was placed in the middle of the mouth and a plastic bite block was placed over the tube. An intravenous propofol infusion was started for continued sedation. The patient was administered 100 mg hydrocortisone to supplement her daily dose of steroid. Muscle relaxation was reversed with 4 mg neostigmine and 0.7 mg glycopyrrolate and four out of four twitches observed with sustained tetanus for three seconds. Immediately prior to extubation,

the bite block was removed, a size nine oral airway was placed, and the oropharynx was suctioned. The patient was extubated without difficulty. The patient was then transferred to the recovery room with all reflexes intact and verbal with no complaints of discomfort. The procedure lasted 55 minutes from beginning of anesthesia to extubation.

Ten minutes after admittance to recovery, the SRNA and CRNA were notified that the patient complained of “swelling and numbness” to the right half of her tongue. On assessment, the patient had slightly slurred speech, negligible dysphagia without aspiration, and a slight motor drift of the tongue to the right. The patient also presented with edema and lack of sensation to the right half of the tongue. The anesthesiologist and pulmonologist were notified of the patient’s symptoms and no further action was taken. The patient met all discharge criteria and was released home after two hours 45 minutes in recovery. Follow-up with the pulmonologist revealed the patient’s symptoms resolved after four days.

## **Discussion**

Hypoglossal nerve injury can be traced to multiple etiologies. Most hypoglossal nerve palsies are caused by tumors, as well as trauma, carotid artery dissection, tonsillectomy, multiple sclerosis, infection, dural arteriovenous fistula, Chiari malformation, otorhinolaryngological and anesthesiological procedures.<sup>3</sup> Nerve injury following airway manipulation remains a rare phenomenon. A study of a series of 339 suspension laryngoscopies by Klusmann et al found the incidence of transient hypoglossal nerve injury to be 1.1 percent.<sup>4</sup>

Understanding of hypoglossal nerve anatomy is crucial to examine the etiology of nerve injury following airway manipulation with anesthesia. The hypoglossal nerve, also known as the twelfth cranial nerve, begins in the medulla oblongata, forms rootlets which perforate the dura mater, and passes through the skull via the hypoglossal canal in the occipital bone. The nerve descends to a point close to the angle of the mandible and then passes between the internal carotid artery and internal jugular vein close in proximity to the vagus nerve. The hypoglossal nerve then reaches the root of the tongue, slightly above the hyoid bone and becomes superficial below the digastric muscle. The hypoglossal nerve gives off lingual branches to the hypoglossal, genioglossal and styloglossal muscles at the anterior border of the hyoglossus before it curves upward towards the tip of the tongue, supplying branches of the tongue.<sup>5</sup> Attempts to narrow the possible etiologies of the nerve injury should include identifying the location of the injury along the nerve path.

Cinar et al. suggest injury can occur during intubation from direct pressure on the nerve from the lateral roots of the tongue by the laryngoscope blade, especially during a difficult intubation when excessive tension on the laryngoscope blade is needed to visualize the vocal cords, further increasing pressure on the tongue.<sup>3</sup> Injury can also occur from compression of the lateral roots of the tongue between the laryngoscope blade and hyoid bone.<sup>3</sup> Stretching of the nerve, as with anterior displacement of the tongue during laryngoscopy or with excessive extension of the neck with the “sniffing” position, has also been implicated as a cause of injury.<sup>1,2</sup> During a rapid sequence induction of anesthesia, it remains common practice to provide the Sellick maneuver or cricoid pressure to prevent the

risk of pulmonary aspiration by applying pressure at the level of the cricoid cartilage throughout endotracheal intubation in the anesthetized patient. Evers et al determined that pressure to the cricoid cartilage during laryngoscopy increases the risk of strain of the hypoglossal nerve.<sup>6</sup>

Injury of the hypoglossal nerve can cause dysphagia and dysarthria due to the loss of motor function of the tongue which manifests as deviation towards the side of the lesion.<sup>3</sup> The patient in the case report also experienced symptoms of lingual nerve damage, such as loss of sensation to the affected side of the tongue. Dziewas notes that in about one quarter of the analyzed cases, ipsilateral damage of the lingual nerve was associated with hypoglossal nerve palsy.<sup>1</sup> The hypoglossal nerve is also implicated as the most common cranial nerve affected by radiation.<sup>2</sup> This is an unlikely cause of the patient's nerve injury since the patient's previous radiation treatment had been localized to the region surrounding her renal cancer. The patient's symptoms resolved within four days of discharge from the hospital. A review of 20 studies showed thirteen cases with complete recovery within one week to four months, three cases with partial recovery, and four cases with no improvement in symptoms.<sup>1</sup>

A total of three laryngoscopies were performed on the patient in the case report, all of which had the possibility to compress the hypoglossal nerve. During the second laryngoscopy, the CRNA used cricoid pressure in an attempt to gain a better view of the glottis leading to the possibility of stretching the nerve. An 8.0 endotracheal tube was inserted to facilitate the bronchoscope. Constant excessive pressure on the lateral roots of the tongue from the large endotracheal tube could be the cause for transient ischemia to the nerve. Yet another

possible origin for the hypoglossal nerve injury could be related to the bite block inserted over the endotracheal tube in the middle of the mouth at the start of the case. Finally, prior to extubation, the insertion of an oral airway and suctioning of the oropharynx could add to the explanation of the patient's nerve palsy. It is difficult to determine the exact cause of the unilateral hypoglossal nerve damage due to the multiple variables involved, most of which have all been implicated by previous research as a cause of nerve damage. Consultation with a neurologist could have been obtained in order to further examine the incident and generate a definitive diagnosis and treatment plan.

## References

1. Dziewas R, Lüdemann P. Hypoglossal nerve palsy as complication of oral intubation, bronchoscopy and use of the laryngeal mask airway. *Eur Neurol.* 2002;47(4):239-243.
2. Keane J. Twelfth-nerve palsy. Analysis of 100 cases. *Arch Neurol.* 1996;53(6):561-566.
3. Cinar U, Akgul G, Seven H, Celik M, Cinar S, Dadas B. Determination of the changes in the hypoglossal nerve function after suspension laryngoscopy with needle electromyography of the tongue. *J Laryngol Otol.* 2004;118(4):289-293.
4. Klussmann J, Knoedgen R, Wittekindt C, Damm M, Eckel H. Complications of suspension laryngoscopy. *Ann Otol Rhinol Laryngol.* 2002;111:972-976.
5. Gray H, Standring S, Ellis H, Berkovitz B. *Gray's anatomy: basis of clinical management.* 39<sup>th</sup> ed. Edinburgh, NY: Elsevier Churchill Livingstone; 2005:794-797.
6. Evers K, Eindhoven G, Wierda J. Transient nerve damage following

intubation for trans-sphenoidal hypophysectomy. *Can J Anaesth.* 1999;46:1143-1145.

**Mentor:** Mike Sadler, CRNA, MSNA

## **Anesthesia Management for Sebastian Syndrome**

Jennifer Henjum, MS  
University of North Dakota

**Keywords:** Sebastian Syndrome, Macrothrombocytopenia, MYH9 mutation, Granulocyte inclusions

Sebastian syndrome (SBS) is an autosomal dominant disorder that causes a mutation of MYH9, the gene that is responsible for encoding the heavy chain of non-muscle myosin IIA (NMMHC-IIA). The enzyme activity of this specific gene is required for motor activity in platelets, leukocytes, kidneys and the cochlea.<sup>1</sup> First defined by Greinacher et al. in 1990, SBS is clinically characterized by thrombocytopenia with giant platelets and granulocyte inclusions.<sup>2</sup> Because platelets are affected, this condition can cause bleeding in the absence of an obvious reason and may create additional complications for patients as they undergo surgery.

### **Case Report**

A 20 year old, 79 kg, 167 cm, ASA III Caucasian female presented for suction dilation and curettage after a spontaneous abortion at 7 weeks, 1 day gestation. The patient was initially diagnosed with SBS at age 5 after excessive bruising. Thereafter, the patient had been symptomatic with Sebastian Syndrome manifestations including chronic thrombocytopenia and macrothrombocytopenia. The patient has been closely followed throughout her life by a pediatric hematologist.

Her surgical history included tonsillectomy and adenoidectomy at age six. During this admission, prior to surgery the patient received aminocaproic acid 3 gm, intranasal desmopressin acetate 20 mcg, and 1 unit of platelets. Medical history revealed that the patient smoked ½ pack per day of cigarettes. Medications taken on a daily basis included prenatal multivitamins. Preoperative laboratory evaluation of the patient revealed the following: Hgb 13.0 g/dl, Hct 38.9 %, WBC 7.87 x 1000/mm<sup>3</sup>, PLT 87 x 10<sup>9</sup>/L, fibrinogen 595 mg/dl, PTT 26 seconds, INR 1.1 and beta hcG 664.4 mIU/ml.

The patient was prepared for surgery in the preoperative holding area where two 18 gauge intravenous catheters were initiated. Lactated Ringers solution was started for fluid management. Following this the patient was premedicated with 2 mg of midazolam and brought to the operating room. After preoxygenation, induction medications included Fentanyl 100 mcg, Lidocaine 40 mg, and Propofol 200 mg given intravenously. A size 4 laryngeal mask airway was inserted into the pharynx. An intranasal temperature probe was inserted and an upper body warming blanket was attached to the patient. Cefazolin 2 gm was administered prior to the start of surgery.

Anesthesia was maintained using 1.9-2.3% Sevoflurane, oxygen 1L/min, and air 1L/min. Additional medications given during the procedure included Fentanyl 100



mcg IV, Dexamethasone 4mg IV, Ondansetron 4 mg IV, and Methergine 0.2 mg IM. At the end of the procedure the laryngeal mask airway was removed without complications and the patient was transported via gurney to the post anesthesia care unit. The patient received a total of 1000 ml of lactated ringers and estimated blood loss was 300 ml. Laboratory values drawn in recovery were WBC  $12.70 \times 1000/\text{mm}^3$ , Hgb 10.4 g/dl, Hct 29.4%, and PLT  $114 \times 10^9/\text{L}$ . The patient was transferred to the obstetrical unit for observation and subsequently discharged after one day.

## Discussion

Anesthesia management for patients with a platelet disorder such as Sebastian Syndrome can be challenging. With this particular disorder, manifestations can range from a mild bleeding tendency to postoperative hemorrhage.<sup>3</sup> Interventions need to be aimed at the prevention of associated risk factors, such as bleeding, in order to maintain adequate intravascular volume. Platelets serve as the body's first line of defense to prevent blood loss. Patients with thrombocytopenia or dysfunctional platelets should be considered as candidates for platelet transfusions. In the preoperative period, prophylactic platelet transfusions should ideally increase the platelet count to approximately  $100,000 \times 10^9/\text{L}$ .<sup>4</sup> Each single unit of platelets that is administered can be expected to raise the platelet count by  $10,000\text{-}20,000 \times 10^9/\text{L}$ .<sup>4</sup> If the patient has a history of prior platelet transfusions, a lesser increase can be expected. The patient in this case report received a unit of platelets in the preoperative holding area due to a platelet count of only  $87 \times 10^9/\text{L}$ . The transfusion was effective by evidence of a postoperative platelet count of  $114 \times 10^9/\text{L}$ . All products

administered to the patient were specifically crossmatched to prevent immune complications such as hemolytic, febrile, urticarial, or anaphylactic reactions. Other complications associated with the transfusion of blood products include noncardiogenic pulmonary edema, posttransfusion purpura, immune suppression, and the possibility of acquiring a viral infection such as hepatitis or HIV.<sup>4</sup>

Another treatment utilized to optimize the patient for surgery was the use of intravenous aminocaproic acid. This medication works as an anti-fibrinolytic agent because plasminogen cannot be activated to plasmin. Without activated plasmin, fibrin and other coagulation factors cannot be degraded. The regulation of the fibrinolytic system with aminocaproic acid protects clots from lysis and reduces the risk of bleeding. Side effects associated with the administration of this medication include hypotension, myopathy, abdominal pain, diarrhea, nasal stuffiness and increased risk of thrombosis because of fibrinolysis inhibition.<sup>5</sup>

Desmopressin (DDAVP) increases factor VIII activity and serves as another therapeutic modality for the treatment of coagulation disorders.<sup>5</sup> The patient in this case received intranasal desmopressin in the preoperative period. According to Althaus (2009), desmopressin was included in the standard surgical protocol for the management of patients with MYH9 disorders.<sup>2</sup> In addition to desmopressin, the other portion of this protocol involved the administration of tranexamic acid. This medication is an analog of aminocaproic acid, as used in this case.<sup>5</sup>

During anesthesia, control of body temperature is another intervention to help control intraoperative blood loss.

Hypothermia, as defined as a body temperature less than 36 °C, can cause coagulopathy by disrupting normal platelet function.<sup>4</sup> In this case, core temperature was monitored continuously. Interventions taken to maintain normothermia and minimize heat loss were the use of a convective forced-air warming blanket and warmed intravenous fluids. These methods were effective as evidenced by temperatures that ranged from 37.1- 37.5 ° C during the perioperative period.

Although patients with MYH9 disorders have a reduced platelet count, they are still at risk for post operative thrombosis. If DDAVP and antifibrinolytics are given, this risk may even be greater than in the normal population.<sup>2</sup> The patient in this case was released from the hospital after one day of observation. No additional thromboprophylactic treatments were administered.

Patients with Sebastian Syndrome undergoing general anesthesia have specific considerations that need to be addressed throughout the perioperative period. Preoperative laboratory values should be assessed and treatments aimed at optimizing the patient prior to surgery to help reduce the risk of possible hemorrhage. Intraoperatively, the patient is closely monitored. Maintaining normothermia during this time will help control blood loss. In the postoperative period, the patient needs

monitoring to continue. The risk of possible thrombosis should be considered even if the patient has a decreased platelet count. By following suggestions for surgical management, the patient with Sebastian Syndrome can safely and effectively be cared for in the perioperative period.

## References

1. Provaznikova D, Geierova V, Kumstrova T, Kotlin R, Mikulenková D, Zurkova K, Matoska V, Hrachovinova I, Rittich S. Clinical manifestation and molecular genetic characterization of MYH9 disorders. *Platelets*. 2009; 20:289-296.
2. Althaus K, Greinacher A. MYH9-related platelet disorders. *Semin Thromb Hemost*. 2009; 35:189-203.
3. Rodriguez V, Nichols WL, Charlesworth JE, White JG. Sebastian platelet syndrome: A hereditary macrothrombocytopenia. *Mayo Clin Proc*. 2003; 78: 1416-1421.
4. Morgan GE, Mikhail MS, Murray MJ. *Clinical Anesthesia*. 4<sup>th</sup> ed. New York: McGraw-Hill Companies, Inc; 2006: 699-702.
5. Katzung BG. *Basic and Clinical Pharmacology*. 10<sup>th</sup> ed. Boston: McGraw-Hill Companies, Inc; 2007: 545-558.

**Mentor:** Kevin C. Buettner, CRNA, MS

## Septic Shock and Habitual Methamphetamine Use

Lee Ranalli, MS  
Kaiser Permanente School of Anesthesia

**Keywords:** sepsis, shock, anesthesia, hypotension, vasopressin

Mortality resulting from septic shock ranges from 50-80%. Ideally, surgery will be delayed if a patient exhibits signs and

symptoms of septic shock until treatment has begun. However, conditions such as necrotizing fasciitis, bowel perforation, infective endocarditis or an infected prosthetic device necessitate immediate surgical intervention. Patients who present to surgery with septic shock are at increased risk for mortality, hemodynamic instability and arterial hypoxemia.<sup>1</sup>

## Case Report

A 26-year-old male (183 cm, 100 kg) was scheduled for surgery to explore and debride his right upper extremity. The patient stated that he had used a “community needle” to inject methamphetamine into his right deltoid two weeks prior. The patient’s right upper extremity was red, inflamed, warm to the touch and hypersensitive to painful stimuli. His medical history was significant for daily methamphetamine abuse for the past ten years.

The patient had nothing by mouth for fourteen hours and had suffered from nausea and vomiting for the past three days. Preoperative vitals included; temperature of 38.5°C, respiratory rate of 22 breaths/min, blood pressure (BP) of 87/54 mmHg and heart rate (HR) of 125 beats/min. A 12-lead electrocardiogram confirmed sinus tachycardia. The patient’s oxygen saturation (SpO<sub>2</sub>) was 95% on four liters of oxygen per nasal cannula.

The emergency room staff administered four liters of intravenous (IV) crystalloid along with IV penicillin and vancomycin. Additionally, IV clindamycin was administered to the patient prior to surgery. The patient was classified as an American Society of Anesthesiologists (ASA) physical class 4E and the potential for postoperative mechanical ventilation was discussed. Abnormal lab results included; an elevated

white blood cell count (WBC) of 14,600 cells/mm<sup>3</sup> and a potassium of 5.3 mEq/L.

Intravenous premedication included metoclopramide, ranitidine, hydrocortisone and midazolam. Once the patient was brought into the operating room, standard anesthesia monitors were applied and preoxygenation was initiated. Intravenous sedation was administered prior to the placement of a left radial arterial line and left internal jugular central line. Central venous pressure (CVP) was monitored with an initial CVP result of 2 mmHg. An arterial blood gas was drawn and the results were consistent with compensated metabolic acidosis.

A rapid sequence induction was performed using fentanyl, etomidate and rocuronium. The trachea was intubated atraumatically with continuous cricoid pressure held until bilateral breath sounds were identified. Post induction, once sevoflurane end-tidal gas concentration reached 0.6%, the patient’s blood pressure stabilized at 74/41 (52). At the time of surgical incision, the systolic blood pressure transiently increased to 84/48 (60) before again decreasing to 72/39 (50) within ten minutes. Due to the extreme sensitivity this patient exhibited with the administration of volatile anesthetic, nitrous oxide was supplemented to assist in maintaining the minimum alveolar concentration  $\geq 0.7$ .

Due to the lability of the patient’s hemodynamics, multiple IV phenylephrine 50 mcg boluses were administered with only minimal and temporary increases in blood pressure. Subsequently, a norepinephrine IV infusion was started at 0.1 mcg/kg/min and was titrated to 0.5 mcg/kg/min to maintain the mean arterial BP > 60 mmHg throughout the remainder of the procedure. Intraoperatively, a total of four liters of

crystalloid and one liter of colloid was administered over the two-hour period. Overall, urine output was minimal throughout the procedure averaging 20 ml/hr.

The patient remained intubated and was transferred to the intensive care unit (ICU). The norepinephrine drip was continued at a rate of 0.5 mcg/kg/min and orders were given to maintain intraoperative ventilatory settings. After arrival in the ICU, the patient's vitals included; HR of 112 beats/min, BP of 86/48 mm Hg, SpO<sub>2</sub> of 98%, CVP of 8 mmHg and temperature of 38.7°C. Continuous IV sedation with fentanyl and midazolam was administered per ICU protocol. Despite all resuscitative efforts, the patient expired five days postoperatively due to multisystem organ failure.

## Discussion

Criteria for septic shock includes the presence of infection, hypotension refractory to fluid administration and the presence of systemic inflammatory response syndrome (SIRS). SIRS was diagnosed in this patient exhibiting a HR > 90 beats/min, temperature > 38°C, RR > 20 breaths/min, and WBC count >12,000 cells/mm<sup>3</sup>.<sup>2</sup> The patient presented in this case study met the established criteria for the diagnosis of septic shock.

The early administration of broad-spectrum antibiotics is correlated with decreased morbidity and mortality that is associated with septic shock.<sup>2</sup> Administration of vancomycin, penicillin and clindamycin prior to surgery provided a broad spectrum of antimicrobial coverage until the specific causative pathogen could be identified and treated appropriately.

In regards to the choice of steroid, hydrocortisone is commonly administered during septic shock and for treatment of refractory hypotension.<sup>3</sup> Invasive monitoring such as an arterial line and a central line are often indicated in septic shock due to the complexity of fluid management and the hemodynamic variability.<sup>1</sup>

The use of etomidate as the primary induction agent is controversial due to preexisting manifestation of adrenal insufficiency in various septic patients.<sup>4</sup> One dose of etomidate has been linked to adrenal suppression resulting in decreased cortisol release for 12-24 hours. However, a high dose benzodiazepine induction has variable onset and induction agents such as thiopental or propofol may worsen the already hemodynamically compromised patient.<sup>3</sup> Ketamine administration was avoided in this case due to the patient's tachycardia (125 beats/min) and his history of methamphetamine use. Extensive history of methamphetamine abuse leads to an increased risk of hemodynamic variability with administration of indirect acting sympathomimetics.<sup>5</sup> In regards to the maintenance of anesthesia, the disadvantage of administering nitrous oxide is the potential for oxidization of vitamin B12 in a patient that is already immunologically compromised.<sup>6</sup>

The history of this patient's chronic methamphetamine abuse for ten years makes this case study notable. Chronic amphetamine abuse and subsequent physiological considerations must be taken into account prior to anesthetic management. Amphetamines stimulate the release of catecholamines which eventually become depleted after chronic use. This depletion of catecholamines can also lead to refractory hypotension.<sup>4</sup> The resultant depletion of endogenous catecholamines may further

complicate the hypotension caused by the septic shock as was evident in this patient. Therefore, a direct-acting vasopressor may be implicated as the agent of choice due to the variable cardiovascular response with indirect acting sympathomimetics.<sup>4</sup>

Hypotension that is refractory to the administration of fluids indicates the need to administer vasopressors. Norepinephrine is a commonly used for management of refractory hypotension that is caused by septic shock.<sup>7</sup> Initial boluses of IV phenylephrine resulted in only minor and transient increases in BP. However, the initiation of high-dose norepinephrine as an IV drip maintained the mean arterial pressure  $\geq 60$  mmHg for the remainder of the case.

Low dose vasopressin may also be used to treat hypotension associated with septic shock. The use of low-dose vasopressin (0.03-0.04 units/min) as an adjunct to norepinephrine can significantly increase BP leading to lower doses of concurrently administered norepinephrine.<sup>8</sup> Low-dose vasopressin therapy also causes dilation of the pulmonary, coronary and renal vasculature. Therefore, the low urine output during this case may have been improved if this intervention was utilized. However, vasopressin must be administered cautiously as high-dose vasopressin ( $\geq 0.05$  units/min) may decrease cardiac output, cause intestinal ischemia or even result in cardiac arrest.<sup>2</sup>

The use of vasopressin as an effective adjunct in septic shock is multifaceted. Circulating vasopressin levels are decreased in the late stages of septic shock. Due to the decrease in circulating vasopressin, up-regulation of vasopressin receptors may occur leading to hypersensitivity of exogenously administered vasopressin. Vasopressin also enhances the sensitivity to

increased circulating catecholamines. The use of vasopressin leads to a decrease intracellular concentration of cyclic guanosine monophosphate (cGMP) which results in a reduction in the synthesis of the potent endogenous vasodilator nitric oxide limiting the extent of vasodilation and hypotension.<sup>9</sup>

Overall, the anesthetic and resuscitative management efforts used for this patient were consistent with interventions outlined in the literature. However, future randomized controlled trials are needed to clarify conflicting findings and further support current treatment guidelines used to treat septic shock.

## References

1. Avidan MS. Infectious diseases. In Hines RL, Marschall KE, eds. *Stoelting's Anesthesia and Co-Existing Disease*. 5<sup>th</sup> ed. Philadelphia: Churchill Livingstone; 2008:478-479.
2. Russell JA. Management of sepsis. *N Engl J Med*. 2006; 355:1699-1713.
3. Ray DC, McKeown DW. Effect of induction agent on vasopressor and steroid use, and outcome in patients with septic shock. *Critical Care*. 2007;11:1-8.
4. Murray H, Marik PE. Etomidate for endotracheal intubation in sepsis. *Chest*. 2005;127:707-709.
5. Hines RL, Marschall KE. Psychiatric disease/substance abuse/drug overdose. In Hines RL, Marschall KE, eds. *Stoelting's Anesthesia and Co-Existing Disease*. 5<sup>th</sup> ed. Philadelphia: Churchill Livingstone; 2008:548-549.
6. van Achterbergh SM, Vorster BJ, Heyns AD. The effect of sepsis and short-term exposure to nitrous oxide on the bone marrow and the metabolism of vitamin B12 and folate. *S Afr Med J*. 1990;78:260-263.

7. Patel BM, Chittock DR, Russell JA, Walley KR. Beneficial effects of short-term vasopressin infusion during severe septic shock. *Anesthesiology*. 2002;96:576-582.
8. Treschen TA, Peters J. The vasopressin system: physiology and clinical strategies. *Anesthesiology*. 2006;105:599-612.
9. Mutlu GM, Factor P. Role of vasopressin in the management of septic shock. *Intensive Care Med*. 2004;30:1276-1291.

**Mentor:** Sass Elisha, CRNA, EdD

## Suspected Trigemino-Cardiac Reflex During Pediatric Tonsillectomy

Jason Goff, BSN

Uniformed Services University of the Health Sciences

**Keywords:** trigemino-cardiac reflex, tonsillectomy, pediatric

The trigemino-cardiac reflex (TCR) is defined as a sudden onset of bradycardia, hypotension, apnea and gastric hypermotility that can occur during central or peripheral stimulation of the trigeminal nerve.<sup>1</sup> The TCR has been reported during surgical procedures involving the cerebellopontine angle, pituitary fossa and cavernous sinus and even upon nasal stimulation.<sup>2-4</sup> This is a case report of a suspected TCR which occurred in a pediatric patient after irrigation of the nares at the conclusion of a tonsillectomy and adenoidectomy surgery.

### Case Report

An ASA I, 5 year old 20 kilogram female presented for a tonsillectomy and adenoidectomy. She had no known drug allergies or surgical history. The patient was transported to the operating room and a pulse oximeter was applied. The patient was administered an inhalation induction with 8% sevoflurane, 3 LPM nitrous oxide and 2 LPM oxygen. A 22 gauge IV was established in the right hand and 50 mcg of fentanyl and 30 mg of propofol were

administered followed by intubation with a 5.0 mm ID cuffed endotracheal tube. Anesthesia was maintained with 0.9 % isoflurane, 1 LPM nitrous oxide and 1 LPM oxygen. The patient maintained spontaneous respiratory effort and the ventilation mode pressure support was used. After induction ondansetron 2 mg and dexamethasone 10 mg were administered for postoperative nausea and vomiting prophylaxis. The surgery proceeded uneventfully and following removal of the tonsils and adenoids, the surgeon irrigated the nares with room temperature saline. At that point the heart rate decreased from 108 to 50 beats per minute (BPM) and the SpO<sub>2</sub> decreased from 100% to 50% for a period of approximately 1 to 2 minutes (Figure #1). The patient's blood pressure did not drop significantly from baseline. The surgeon was asked to stop the irrigation, isoflurane and nitrous oxide administration ceased and the patient was manually ventilated with 100% oxygen. The heart rate quickly increased to 140 BPM and the SpO<sub>2</sub> returned to 100%. The surgery was finished and after meeting extubation criteria, the patient was extubated and transported to the recovery room in stable condition. She was discharged home several hours later without complication.

## Discussion

The TCR is a variant of the more recognized physiological response called the oculocardiac reflex (OCR). The OCR can be elicited in all age groups during a number of ocular procedures where traction is placed on the extraocular muscles or pressure is placed upon the globe.<sup>5</sup> Stimulation of the TCR and OCR results in subsequent parasympathetic discharge via the gasserian ganglion stimulating an afferent reflex arc leading to activation of the M2 receptors of the myocardium resulting in bradycardia.

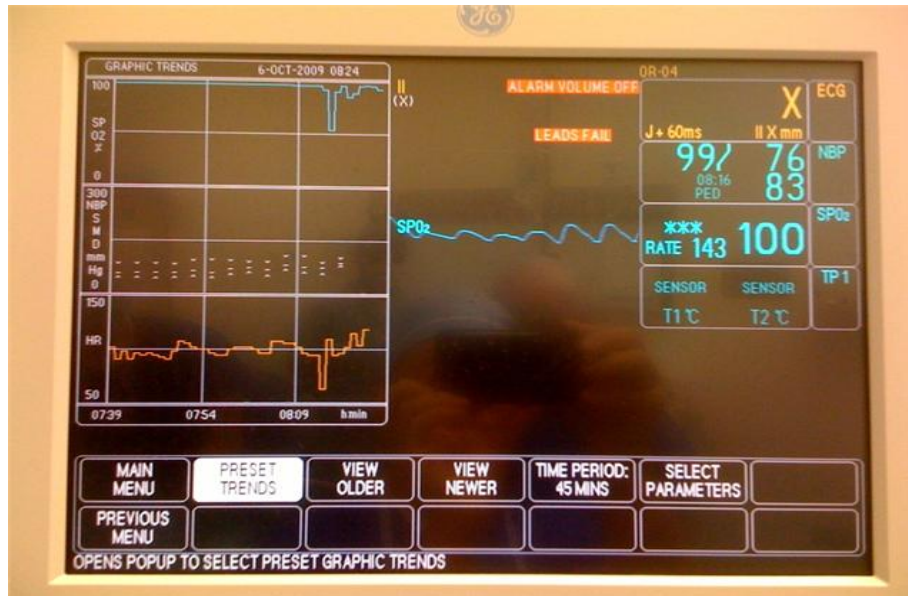
The TCR has been described in the literature as being an oxygen conservation reflex very similar to the diving reflex and is seen in hibernating animals to decrease their basal metabolic demands during the winter season.<sup>6</sup> When stimulated by a lack of blood or oxygen the reticulospinal neurons of the rostral part of the ventral medulla cause an increased regional blood flow without changing the cerebral metabolic consumption of oxygen.<sup>7</sup>

Although the OCR has received a lot more attention in the past, the past two decades of surgical breakthroughs have enabled surgeons to gain access to the pituitary fossa, cavernous sinus and other areas within the skull where the TCR is more likely to be elicited. Maxillofacial procedures such as Lefort-1 osteotomies and midface facial reductions have been documented to elicit the TCR.<sup>8</sup> In addition, procedures involving turbinate surgery can trigger the TCR through stimulation of the maxillary branch of the trigeminal nerve.<sup>9</sup> In our case we believe the instillation of normal saline triggered the TCR via the anterior ethmoidal nerve, which is a portion of the nasociliary branch of the ophthalmic division of the trigeminal nerve.

In the case described above, the bradycardia may have contributed to a ventilation/perfusion mismatch resulting in a transient hypoxic state. The literature has described the TCR as having the potential to create a period of apnea, which might also explain the hypoxemia.<sup>8</sup> During the event we did not note a period of apnea due to our fixation with how quickly the oxygenation status and bradycardia manifested and our subsequent initiation of manual ventilation. In our case, the bradycardia and hypoxia both quickly resolved with cessation of the nasal irrigation and treatment with positive pressure ventilation with 100% FiO<sub>2</sub>.

If the TCR does occur it is recommended that the surgeon be informed to stop triggering the reflex (i.e., irrigating the nares, placing traction on the ocular globe, etc.). At the same time the patient should be manually or mechanically ventilated with 100% oxygen. If the bradycardia does not resolve the anesthesia professional should consider administering an anticholinergic. Some reports suggest prophylactic treatment with an anticholinergic agent (i.e., glycopyrrolate or atropine) may minimize the risk of developing the TCR.<sup>8</sup> However, this is not routinely performed based on the fact that anticholinergic drugs can cause dysrhythmias.<sup>8</sup> If these interventions do not resolve the bradycardia and hypoxia, a differential diagnosis approach should be used to search for and treat other possible causes of brady arrhythmias.

In conclusion, the TCR is a physiological response that anesthesia professionals should be familiar with and prepared to treat. Primary means of prevention is avoiding triggering stimuli.<sup>8</sup> Research suggests that hypercapnea, hypoxia, acidosis and light anesthesia are factors that can contribute to development of the TCR.<sup>10</sup>



**Figure 1.** Graphic trends view of the SpO2 and heart rate as displayed throughout the course of the case reflecting the hypoxic and bradycardic event.

## References

- Schaller B. Trigemino-cardiac reflex. A clinical phenomenon or a new physiological entity? *J Neurol.* 2004;251: 658-665.
- Schaller BJ, Buchfelder M, Knauth M. Trigemino-cardiac reflex during skull base surgery: a new entity of ischaemic preconditioning? The potential role of imaging. *Eur J Nucl Med Mol Imaging.* 2006;33: 384-385.
- Schaller B. Trigemino-cardiac reflex during transphenoidal surgery for pituitary adenomas. *Clin Neurol Neurosurg.* 2005;107: 468-474.
- Bailey PL, Sinus arrest by trivial nasal stimulation during alfentanil nitrous oxide anaesthesia. *Br J Anaesth.* 1990;65: 718-720.
- Arasho B, Sandu N, Spiriev T, et al. Management of the trigemino-cardiac reflex: Facts and own experience. *Neuro India.* 2009;57:375-380.
- Heistad DD, Kontos HA. Cerebral circulation. In: Shephard JT, Abboud FM eds. *Handbook of Physiology. Circulation. Peripheral Circulation and Organ Blood Flow.* Vol. 3. Bethesda, MD: *Am Physiol Soci*; 1983: 137-182.
- Stephenson R, Jones DR, Bryan RM. Regional cerebral blood flow during submergence asphyxia in Pekin duck. *Am J Physiol Regul Integr Comp Physiol.* 1994; 266: 1162-1168.
- Schaller B, Cornelius JF, Prabhakar H, et al. The trigemino-cardiac reflex: An update of the current knowledge. *J Neurosurg Anesthesiol.* 2009;21:187-195.
- Bainton R, Lizi E. Cardiac asystole complicating zygomatic arch fracture. *Oral Med Oral Pathol.* 1987;64:24-25.
- Baxandall ML, Thorn JL. The nasocardiac reflex. *Anaesthesia.* 1988;43:480-481.

**Mentor:** Dennis Spence, CRNA, PhD



## Treatment of Post-Dural Puncture Headache with Ketoralac

Chad Moore, BSN

Uniformed Services University of the Health Sciences

**Keywords:** post-dural puncture headache, epidural anesthesia, neuraxial anesthesia complications, low-pressure headache

Epidural anesthesia offers the benefit of pain control to parturients with minimal effects on the fetus, but if the dura is punctured during the procedure, post-dural puncture headache (PDPH) may ensue. PDPH may be caused by fluid leaking out of the subarachnoid space and the resultant volume deficit,<sup>1</sup> or a reflexive dilation of the cerebral vessels.<sup>2</sup> Intravenous ketorolac is a treatment successfully utilized for migraine and tension-type headaches, which have a vascular component to their pathology.<sup>3</sup> If the cause is vascular in nature, then ketorolac should be similarly effective in treating PDPH.

### Case Report

A 23-year-old gravida 2 and para 1 (G<sub>2</sub>P<sub>1</sub>) had a spontaneous vaginal delivery at 39 2/7 weeks of gestation. The labor progressed without obstetric complication and analgesia was provided by continuous lumbar epidural infusion of 0.125% bupivacaine and fentanyl 2 mcg/mL. During the placement of the epidural catheter, inadvertent dural puncture at the L4-5 interspace was evidenced by brisk return of cerebrospinal fluid (CSF) through the 17-gauge Touhy needle. The CSF was injected back into the subarachnoid space and the needle was removed. The second attempt at epidural placement was successful at the L3-4 interspace with the loss-of-resistance technique using air and saline, and the catheter was threaded into the space. Placement was confirmed using a 3 mL test dose of 1.5% lidocaine with

epinephrine 1:200,000, and a T6 level of analgesia was subsequently achieved with the continuous infusion.

Following delivery, the patient complained of a slight frontal headache overnight of 1-3/10 severity that was not positional in nature. The obstetric anesthesia service was contacted by the nursing staff to evaluate the patient at 20 hours following delivery, when the patient complained of a frontal headache of 7/10 severity while standing that was relieved to 5/10 when supine. Her symptoms were suggestive of PDPH. The obstetric team followed the anesthesia service's recommendation to administer intravenous ketorolac 30 mg as an initial treatment for the headache. The ketorolac was chosen as a first-line therapy because it offered low risk of adverse events with the potential for fast relief of her symptoms. Unimplemented treatment options included fluid resuscitation, caffeine, abdominal binder, epidural blood patch, or to offer rest with time as the remedy. The patient's headache completely resolved within 30 minutes of administration. The patient remained in the hospital for another night of observation, without any recurrence of symptoms. The patient was instructed to contact anesthesia if symptoms returned and was discharged home by the obstetric team.

The patient was contacted at three weeks post-partum to inquire about any recurrence of symptoms. She had a positional headache that began 24 hours after her return home, two days after the ketorolac treatment. This headache was 7/10 severity when standing but 3/10 when supine. The headache was frontal and continuous, non-throbbing when

supine, but became throbbing when standing. The symptoms spontaneously resolved at five days. The patient had been taking ibuprofen 800 mg PO three times daily and continued oral hydration but did not incorporate caffeine into her diet.

## Discussion

Parturients have a risk of less than 2% of developing a headache lasting more than 6 hours regardless of anesthetic technique.<sup>4</sup> This risk greatly increases following accidental dural puncture to 52%.<sup>5</sup> Of these patients with a PDPH, 66% classify their headaches as severe and these headaches often limit their participation in activities of daily living and caring for their newborn children.

Differential diagnosis for this patient included PDPH, tension headache, migraine headache, and musculoskeletal headache. PDPH was suspected in this patient due to appearance of some of the typical confounding factors, such as worsening headache when standing and a recent history of dural puncture with a large bore cutting needle.<sup>1</sup> Treatment includes conservative measures such as analgesics and caffeine, or the more invasive option of the epidural blood patch.<sup>4</sup> The treatment is ultimately based on the patient's willingness to participate. Although highly effective, the epidural blood patch is met with potential complications and the idea may not be well received by a parturient that has just experienced a PDPH resulting from her first epidural placement.<sup>6</sup>

Research on specific therapies for PDPH is limited, and a specific link to treatment with intravenous NSAID therapy was not found in the literature search for this report; however an oral NSAID similar to ketorolac, diclofenac, has been reported as a

standard initial therapy for patients with PDPH in one institution.<sup>7</sup> NSAID therapy primarily acts by inhibiting two cyclooxygenase isoforms, COX1 and COX2. This enzymatic inhibition is responsible for the anti-inflammatory effects through the downstream inhibition of prostaglandin synthesis. Shearing forces on endothelial cells induce localized COX2 activity, which is pro-inflammatory.<sup>8</sup> The COX2 inhibition in the presence of shearing forces involved in PDPH provides a possible mechanism of action for the drug's effect. NSAIDs are known to decrease nitric oxide synthase activity,<sup>8</sup> which would then inhibit nitric oxide-induced dilation of vascular smooth muscle.<sup>9</sup> The dilated cerebral vessels would presumably constrict, lessening the severity of the headache. The case presented here suggests that conservative treatment with intravenous ketorolac may offer some benefit, at least initially, to the patient with PDPH. The treatment with oral ibuprofen did not seem to provide a measurable benefit, although there was no observed time period when treatment with ibuprofen was withheld. The headache could have been more severe had this treatment regimen not been followed. When aspirin is used as the baseline for analgesic and anti-inflammatory comparison, ibuprofen has been characterized as equipotent, but ketorolac has been described as a potent analgesic and poor anti-inflammatory agent when compared to aspirin.<sup>8</sup>

Had the patient expressed an increasing severity of headache that was not well managed with conservative therapy, an epidural blood patch (EBP) should have been considered. Epidural blood patches treat the headache at the level of the underlying cause, stopping the leaking cerebrospinal fluid. Considered a definitive treatment for PDPH, the EBP is not met without risk of further trauma, bleeding, and

infection at the site.<sup>1</sup> Up to 70% of patients choosing EBP will gain relief from their PDPH on the first attempt.<sup>7</sup>

The aforementioned options should be weighed and offered to the patient with PDPH. With minor symptoms, more conservative approaches can be offered first, such as rest, hydration, and mild analgesics.<sup>10</sup> With severe symptoms, the anesthetist should offer the course of treatment to a reliable outcome, such as with the epidural blood patch. If the patient has objections to epidural blood patch, the prospect of intravenous ketorolac should be explored if no contraindications exist. Contraindications to ketorolac therapy may include peptic ulcer, renal, and liver disease.<sup>10</sup> It is unclear whether intramuscular injection would have offered the same benefit, but that option may be more applicable because feasibility and cost of providing intravenous medication on an outpatient basis may limit its routine use. Oral ketorolac is also available but time to onset may have a role in the perceived efficacy of the drug. The literature currently available that addresses NSAIDs as a treatment for PDPH is sparse and further study is warranted.

## References

1. Macarthur A. Postpartum headache. In: Chestnut DH, ed. *Chestnut's obstetric anesthesia: principles and practice*. 4th ed. Philadelphia: Mosby/Elsevier; 2009:677-700.
2. Ortiz GA, Bianchi NA, Tiede MP, Bhatia RG. Posterior reversible encephalopathy syndrome after intravenous caffeine for post-lumbar puncture headaches. *AJNR Am J Neuroradiol*. Mar 2009;30(3):586-587.
3. Friedman D, Feldon S, Holloway R, Fisher S. Utilization, diagnosis, treatment and cost of migraine treatment in the emergency department. *Headache*. Sep 2009;49(8):1163-1173.
4. Chan TM, Ahmed E, Yentis SM, Holdcroft A. Postpartum headaches: summary report of the National Obstetric Anaesthetic Database (NOAD) 1999. *Int J Obstet Anesth*. Apr 2003;12(2):107-112.
5. Choi A, Laurito CE, Cunningham FE. Pharmacologic management of postdural puncture headache. *Ann Pharmacother*. Jul-Aug 1996;30(7-8):831-839.
6. Sharma A, Cheam E. Acupuncture in the management of post-partum headache following neuraxial analgesia. *Int J Obstet Anesth*. Oct 2009;18(4):417-419.
7. Sprigge JS, Harper SJ. Accidental dural puncture and post dural puncture headache in obstetric anaesthesia: presentation and management: a 23-year survey in a district general hospital. *Anaesthesia*. Jan 2008;63(1):36-43.
8. Burke A, Smyth E, FitzGerald GA. Analgesic-antipyretic and anti-inflammatory agents; pharmacotherapy of gout. In: Goodman LS, ed. *Goodman & Gilman's the pharmacological basis of therapeutics*. 11th ed. New York: McGraw-Hill; 2006.
9. Buchwalow IB, Podzuweit T, Bocker W, et al. Vascular smooth muscle and nitric oxide synthase. *FASEB J*. Apr 2002;16(6):500-508.
10. Diamond ML. Emergency department management of the acute headache. *Clin Cornerstone*. 1999;1(6):45-54.

**Mentor:** Dennis Spence, CRNA, PhD

## Intraoperative Pulmonary Embolism

Laurel Schooler, MS  
University of Southern California

**Keywords:** pulmonary embolism, deep vein thrombosis, thromboembolism, obesity, prophylaxis

Pulmonary embolism (PE) is a serious and potentially fatal complication that can occur intraoperatively. Manifestations of PE are often nonspecific and transient, which makes intraoperative diagnosis exceedingly difficult.<sup>1</sup> The prevalence of perioperative PE is unknown and despite significant advances in the prophylaxis and diagnosis of deep vein thrombosis (DVT) and resultant PE, the mortality and recurrence rate remains high.<sup>2,3</sup> An estimated 10% of all hospital deaths are attributed to PE, which remarkably is the most preventable cause of death in hospitalized patients.<sup>1</sup> The following case study will focus on the recognition and treatment of intraoperative pulmonary embolism.

### Case Report

A twenty-two year old 110 kg male presented for a lower extremity irrigation and debridement with the potential of a rotational muscle flap for reconstruction. A week prior to presentation he had been in a motorcycle accident requiring an open reduction and internal fixation of the tibia and fibula with placement of an intramedullary nail. He remained hospitalized during this time because of his open wound which needed debridement and soft tissue reconstruction. His past medical history included morbid obesity with a body mass index of  $41\text{kg/m}^2$ . He was not taking any medications and denied a history of smoking.

Preoperative vital signs included a blood pressure of 118/71 mmHg, pulse of 88 bpm, respiratory rate of 12 breaths per minute and SpO<sub>2</sub> of 98% on room air. His preoperative chest radiograph was normal. Laboratory values were also within normal limits and included an arterial blood gas (ABG) as follows; pH 7.38, PCO<sub>2</sub> 41 mm Hg, PO<sub>2</sub> 124 mm Hg, HCO<sub>3</sub> 25 mEq/liter on room air. Following a standard induction with lidocaine 100 mg IV, propofol 200 mg IV, fentanyl 300 mcg IV and rocuronium 90 mg IV, the trachea was successfully intubated. Anesthesia was maintained with sevoflurane at 2.8 % and a mixture of 1 L/min oxygen and 1 L/min air.

Approximately ten minutes after surgical incision and twenty minutes after induction of anesthesia, the SpO<sub>2</sub> fell precipitously to 92% and the patient became tachycardic with a heart rate of 106 bpm. The end-tidal carbon-dioxide was 30 mmHg. The chest was then auscultated to reveal diminished breath sounds on the right side. After ensuring proper endotracheal tube (ETT) placement, suctioning, switching the patient to 100% FiO<sub>2</sub> and administering six puffs of albuterol, the patient's oxygen saturation remained at 92%. An ABG was then drawn, a chest radiograph ordered, and the surgical team was notified of the event. The chest radiograph revealed hypoventilation with low lung volumes and was negative for pneumothorax. The ABG results were as follows: pH 7.47, PCO<sub>2</sub> 36 mm Hg, PaO<sub>2</sub> 69 mm Hg, and HCO<sub>3</sub> 27 mEq/liter on 100% oxygen.

Due to the patient's low PaO<sub>2</sub>, SpO<sub>2</sub>, and no response to medical intervention, the

surgical procedure was discontinued. The patient remained sedated and intubated and was transported to the intensive care unit. There, his vital signs stabilized. He had a blood pressure of 122/76, pulse of 82 bpm, and an SpO<sub>2</sub> of 98% on 100% FiO<sub>2</sub> with ventilatory support. A computed tomography (CT) of the chest was obtained. Unfortunately, the CT was unreadable due to the patient's body habitus and poor timing of the contrast administration. As a result, the pulmonary arteries could not be well visualized. Additional tests were ordered to rule out PE including a D-dimer test which was positive. A lower extremity ultrasound was also ordered which revealed a thrombus of the popliteal vein in the operative leg.

An inferior vena cava (IVC) filter was then inserted and the patient was started on a DVT prophylaxis regimen of warfarin and heparin. The following day after meeting extubation criteria, the patient was extubated. He was ultimately discharged home after successful completion of surgery on warfarin therapy one month later.

## Discussion

Thromboses (and subsequent emboli) develop following endothelial damage with resultant platelet activation, adhesion and aggregation into a platelet clot. Obese patients, such as this patient, are twice as likely to develop a thrombosis as non-obese individuals.<sup>3</sup> The increased risk is presumably from the effects of polycythemia and increased abdominal pressure in deep veins.<sup>3</sup>

Virchow's triad is comprised of three factors which are common causes of DVT. These factors can be brought about by typical conditions under anesthesia. The first component is stasis as a result of venous pooling from the supine position.<sup>2</sup> The

second component is hypercoagulability which occurs from decreased clearance of procoagulant factors.<sup>2</sup> The final component is intimal injury following excessive vasodilation caused by vasoactive amines and anesthesia.<sup>2</sup> Surgical insult makes each patient susceptible to thromboses and the anesthetized patient is highly subject to venous pooling, hypercoagulability, and intimal injury.

Multifactorial components attribute to the formation of a DVT and resultant PE which make them difficult to diagnose. Symptoms of a PE may include: hypotension, dyspnea, tachypnea, tachycardia, wheezing, pleuritic or substernal chest pain, cough, fever, rales, a pleural rub, loud pulmonic second heart sound, bulging neck veins, or hemoptysis, some of which are masked in the anesthetized patient.<sup>3</sup> These are caused by the embolism obstructing pulmonary blood flow which results in ventilation without perfusion. Symptoms of PE run on a continuum from a normal ABG to a sudden cardiovascular collapse. One of the hallmark signs of a PE is a reduced end tidal carbon dioxide. The only symptoms this patient exhibited were tachycardia, wheezing, and a low SpO<sub>2</sub>.

In most cases, PE is treated conservatively, with anticoagulants to prevent clot extension. In the case of a PE which causes significant hemodynamic compromise, definitive treatment is surgical embolectomy. The intraoperative management of a PE includes supporting vital organ function and minimizing anesthetic-induced myocardial depression.<sup>3</sup> In the event of a suspected intraoperative PE, anesthesia can ideally be maintained with any combination of drugs that will minimize significant myocardial depression, however there are a few recommendations. Some of these include avoiding the

administration of nitrous oxide or histamine releasing medications which can further exacerbate the PE by increasing pulmonary resistance.<sup>3</sup> An increase in FiO<sub>2</sub> with discontinuation of nitrous oxide will allow vasodilation of pulmonary vasculature with a reduction in dead space ventilation.

Other recommended treatments for PE can be focused on decreasing the resistance of the pulmonary vasculature. Medications such as nifedipine, hydralazine, nitroglycerin, prazosin, phentolamine, and nitric oxide all have the potential to dilate the pulmonary vasculature subsequently decreasing pulmonary resistance.<sup>5</sup> It is also recommended to adequately fluid resuscitate the patient and avoid prolonged periods of dehydration which can lead to sludging of blood and potentiate thrombus formation.<sup>5</sup> Additional interventions include avoidance of hypoxemia, hypercapnia, acidosis, lung hyperinflation, hypothermia or increased systemic vascular resistance.<sup>5</sup>

This patient was not given any medications that would provoke histamine release or significant myocardial depression. Nitrous oxide was not administered, and he was appropriately fluid resuscitated based on a fluid plan that was calculated prior to induction of anesthesia. No adjunct pulmonary vasodilators were administered but this treatment could have been advantageous in the management of PE.

Other than morbid obesity this was an otherwise healthy patient whose presentation of PE was atypical. His only signs and symptoms suggestive of PE were tachycardia, diminished breath sounds, wheezing and SpO<sub>2</sub> of 92%, however these are not exclusive to PE. Because of this, several practical interventions were first attempted to determine the etiology of symptoms and rule out pulse oximetry probe

dislodgement, pain, ETT position, bronchospasm, and a clogged or kinked ETT. Interventions included checking the position of the pulse oximetry, administering adjunct opioids for analgesia, auscultating the chest for abnormal breath sounds, administration of a bronchodilator for wheezing, suctioning respiratory secretions, and increasing the FiO<sub>2</sub> to increase SpO<sub>2</sub>.

In conclusion, this patient would have benefited from DVT prophylaxis because he was an obese, non-mobile, trauma patient having lower extremity surgery requiring general anesthesia.<sup>6</sup> According to clinical guidelines, this patient was considered at a moderate risk for PE. Prophylaxis however was not initiated. Anesthesia practitioners should consider PE as a potential complication when administering anesthesia to any patient, and recognize that presentation is non-specific and may be variable. In a patient with abrupt oxygenation deficiencies, a presumptive diagnosis of PE should be made when other causes are ruled out.

## References

1. Palateri G, Cosmi B. Emerging Drugs for Venous Thromboembolism. *Expert Opin Emerg Drug*. 2010;15(1):107-17.
2. Mood GR, Tang WH. Perioperative DVT Prophylaxis. <http://emedicine.medscape.com>. Updated January 14, 2009. Accessed March 6, 2010.
3. Kirip V. Respiratory Disease. In: Hines RL, Marschall KE. *Stoelting's Anesthesia and Co-Existing Disease*. 5<sup>th</sup> ed. Philadelphia, PA: Churchill Livingstone; 2009:191-193.
4. Lippi G, Cervellin G, Franchini M, Favaloro, E. Biochemical markers for the diagnosis of venous thromboembolism: the past, present and

- future. *J Thromb Thrombolysis*. 2010:1-13.
5. Roizen, MF, Fleisher, LA. *Miller's Anesthesia*. 7th ed. Philadelphia, PA: Churchill Livingstone; 2009:1108-1111.
  6. Hirsh J, Guyatt G, Albers GW, Harrington R, Schuneman HJ, and the American College of Chest Physicians.

Antithrombotic and thrombolytic therapy: American College of Chest Physicians evidence-based clinical practice guidelines. *Chest*. Jun 2008; 133:110S-11.

**Mentor:** Michele Gold, CRNA, PhD

## Anesthetic Management of Felty's Syndrome

Felicity Rensberger, MS  
University of Southern California

**Keywords:** Rheumatoid arthritis, Felty's syndrome, pancytopenia, thrombocytopenia, neutropenia, difficult intubation, regional anesthesia

Rheumatoid arthritis (RA) is an autoimmune inflammatory disease affecting an estimated 1.3 million adults in the United States, or 0.6% of the adult population.<sup>1</sup> RA is characterized by symmetrical polyarthropathy, particularly of the proximal interphalangeal and metacarpophalangeal joints, as well as systemic involvement. Both cervical spine involvement and cricoarytenoid arthritis affect airway management of the RA patient. Systemic features include vasculitis of small and medium arteries, cardiovascular and pulmonary complications, and neuropathies. Hematologic abnormalities may also occur.<sup>2</sup> Felty's syndrome is RA complicated by splenomegaly and neutropenia, with occasional anemia and thrombocytopenia.<sup>3</sup>

### Case Report

A 38 year-old, 53 kg female, American Society of Anesthesiologists (ASA) physical classification III, presented for an outpatient irrigation and debridement (I and D) with split thickness skin graft of a chronic left

lower extremity wound. Her medical history was significant for debilitating RA with Felty's syndrome characterized by chronic neutropenia, anemia, thrombocytopenia and splenomegaly, cryptogenic cirrhosis with normal synthetic liver function, gastroesophageal reflux disease (GERD), and a remote positive purified protein derivative skin test for which she received drug treatment for nine months. Medications included hydroxychloroquine, prednisone, omeprazole and adalimumab, all taken the morning of surgery. Her surgical history was significant for a recent I and D of this wound, during which anesthesia practitioners were unable to intubate the patient despite utilizing a variety of techniques including fiberoptic technology, due to inability to pass the endotracheal tube (ETT) through the visualized vocal cords.

Preoperative cervical spine X-ray revealed minimal anterolithesis suggestive of ligamentous laxity. Her preoperative complete blood count (CBC) was significant with a white blood cell count (WBC) of  $5.5 \times 10^9/L$ , an undetectable platelet count, hemoglobin of 6.6 g/dL and hematocrit of 20.8%. Vital signs were within normal limits. The airway exam revealed a Mallampati classification II, free range of

motion (ROM) of cervical spine without radicular symptoms, and slight warmth over the larynx, indicating arytenoidal inflammation. She reported a history of occasional hoarseness and tenderness with swallowing but denied current symptomology.

After premedication with midazolam 2 mg intravenously (IV) the patient was transported to the operating room (OR) where standard anesthesia monitors were placed. The patient's heart rate was noted to be 120 beats per minute (BPM) and fentanyl 50 mcg IV was given while oxygen at 10 liters per minute was administered via facemask. A modified rapid sequence induction was performed with cricoid pressure. Lidocaine 80 mg and propofol 200 mg IV were given and the ability to mask ventilate was confirmed with a single breath prior to muscle relaxant administration, due to concerns regarding the ability to intubate. Succinylcholine 100 mg IV was administered with an additional dose of fentanyl 50 mcg IV. Direct laryngoscopy (DL) with cervical spine stabilization was performed utilizing a MacIntosh #3 laryngoscope blade, and the trachea was orally intubated with a lubricated 6.0 endotracheal tube (ETT). Slight erythema of the vocal cords was noted.

Dexamethasone 8 mg IV and rocuronium 40 mg IV were administered after intubation and mechanical ventilation was provided.

General anesthesia was maintained with desflurane 2-6% end tidal concentration and muscle relaxation was maintained with rocuronium 20 mg IV. Fentanyl 500 mcg IV was titrated in 50 mcg increments for analgesia. The patient was transfused with one unit of packed red blood cells (PRBCs) and one unit of platelets as a result of the preoperative CBC. At the end of the procedure the estimated blood loss was 20

mls. Emergence from anesthesia and extubation were uneventful. The patient was transported to the post anesthesia care unit with stable vital signs and another unit of PRBCs and platelets were administered. The post-procedure CBC revealed: a WBC of  $3.3 \times 10^9/L$ , platelets of  $118 \times 10^9/L$ , a hemoglobin of 9.3 g/dL and a hematocrit 28.2%. Her CBC remained stable for two days and she was discharged without complications.

## Discussion

The anesthetic management of this patient presented a number of unique challenges due to her history of difficult intubation and Felty's syndrome with severe pancytopenia. Felty's is a rare condition found in less than 1% of RA patients.<sup>4</sup> In addition to severe articular disease, patients present with splenomegaly and leukopenia, with predominantly low neutrophil counts.<sup>4</sup> Neutropenia is the most clinically significant symptom, leading to frequent infections. Infections of the oropharynx and nasopharynx, cellulitis and pneumonia are common and more likely to progress to sepsis than in the non-immunocompromised patient. These infections may be characterized by decreased localized symptoms but intact febrile responses secondary to an intact cell mediated immune function, which also prevents an increased incidence of opportunistic infection.<sup>5</sup> The pathogenesis of Felty's neutropenia is complex, but it appears to be closely related to disorders such as T-cell large granulocyte lymphocyte leukemia.<sup>5</sup> Proposed mechanisms include cell mediated suppression of myeloid precursors, decreased colony stimulating activity, and non-immunoglobulin humoral factor suppression of granulopoiesis. Increased destruction and splenic sequestration of neutrophils has also been found.<sup>4</sup>



Sequestration alone cannot account for the degree of neutropenia found in Felty's patients, as there is no correlation between the degree of splenomegaly and levels of neutrophils. However, the degree of splenomegaly has been positively correlated to the degree of both anemia and thrombocytopenia.<sup>5</sup>

The pharmacologic treatment for Felty's syndrome is non-steroidal anti-inflammatory drugs (NSAIDs) for pain management and steroids equivalent to prednisone 10 mg/day or less.<sup>6</sup> The current recommendation is early initiation of treatment with disease modifying antirheumatic drugs such as methotrexate, hydroxychloroquine, sulfasalazine, cyclosporine or a combination of these drugs, which may slow the disease progression and limit damage to joints.<sup>6</sup> Although methotrexate is the first line treatment for cases of severe RA, complications such as liver disease with abnormal liver function tests, low WBC and platelet counts, pneumonitis and lymphomas can occur. Patients who cannot tolerate methotrexate due to toxicity may be placed on hydroxychloroquine, which is documented to have positive effects on neutropenia, although it is less effective than methotrexate in treating articular symptoms.<sup>7</sup> The side effects of NSAIDs include inhibition of cyclooxygenase and limitation of platelet function, and gastrointestinal distress.<sup>2</sup> Steroids are associated with decreased wound healing and increased infection and hyperglycemia.<sup>2</sup> Intraoperative prophylaxis with medications such as omeprazole, as well as a dose of steroids equivalent to hydrocortisone 100 mg, may be required in patients on long term NSAID and steroid therapy.<sup>3</sup> Of interest in this patient, the side effects of adalimumab include increased risk of infection, particularly reactivation of her previously treated tuberculosis.

Hydroxychloroquine has few severe side effects.<sup>6</sup>

Patients with RA, with or without Felty's syndrome, commonly present airway management challenges. The cervical spine is frequently involved and may demonstrate atlanto-axial subluxation accompanied by odontoid process effacement in 40-85% of patients, regardless of symptomology.<sup>8</sup> Temporomandibular joint involvement is common and may be noted as limited mouth opening on exam.<sup>8,9</sup> The cricoarytenoids may be involved in 26-86% of cases, creating a difficult intubating environment.<sup>3</sup> In this case, X-ray demonstrated laxity but not subluxation, and physical exam revealed normal ROM of the neck as well as full mouth opening. However, her history of hoarseness and tenderness on swallowing was suspicious for cricoarytenoid involvement.

The recommended and most common anesthetic technique for RA patients is regional anesthesia whenever feasible.<sup>8,9</sup> Although there is a paucity of research regarding safe platelet levels during neuraxial anesthesia, pancytopenia is a contraindication to regional anesthesia due to concern for creating an epidural hematoma, or central nervous system infection. Both a case study and letter presenting original research indicate that anesthesia practitioners are not providing regional anesthesia to patients with platelet counts less than  $50 \times 10^9/L$ .<sup>10,11</sup> Likewise there are few guidelines available regarding neuraxial anesthesia for leukopenic or neutropenic patients. The American Society of Regional Anesthesiologists recommendations regarding regional blockade in the immunocompromised patient state that there is a theoretical risk with this technique and that the choice of

technique must be made on an individual basis, weighing the risks and benefits.<sup>12</sup>

Although a prior difficult intubation has been found to be a positive predictor of subsequent difficult intubations ( $p < 0.0001$ ),<sup>13</sup> for this patient it seemed clear that the risks of regional blockade outweighed the possible inability to intubate. The decision was made to utilize succinylcholine after determining that the patient could be ventilated with a mask, and to attempt intubation by DL with a Glidescope® Video Laryngoscope (Verathon Inc, Bothell, WA) immediately available should intubation by DL fail. A review of the anesthesia record of her prior surgery revealed that the vocal cords were easily visualized, but difficulty was encountered passing the ETT. Therefore, a #6.0 ETT was chosen, rather than the #7.0 ETT that had been previously attempted. Additionally, the tip was lubricated to facilitate easy passage through the cords. There is support in the literature for intubation via DL in the RA patient, provided that care is taken to maintain cervical spine stability.<sup>9</sup> A case report by Papneja, Sawhney, Singh, and Uppal describes a patient with Felty's syndrome who was successfully intubated via DL utilizing succinylcholine with no adverse sequelae.<sup>3</sup>

The patient with Felty's syndrome presents a challenge, with relative contraindications to both regional and general anesthesia. In this case, another choice would have been to transfuse platelets prior to regional anesthesia. However, after weighing multiple factors general anesthesia with intubation of the trachea was chosen and administered without adverse consequences.

## References

1. Helmick CG, Felson DT, Lawrence RC, et al. Estimates of the prevalence of arthritis and other rheumatic conditions in the united states. *Arthritis Rheum* 2008;58(1):15-25
2. Schwartz JJ. Skin and musculoskeletal diseases. In: Hines, RL, Marschall, KE eds. *Stoelting's Anesthesia and Co-Existing Disease*. 5<sup>th</sup> ed. Philadelphia, PA: Elsevier; 2008:455-57
3. Papneja C, Sawhney R, Singh B, Uppal R. Anaesthetic considerations in a patient with felty's syndrome for major abdominal surgery. *J Anaesth Clin Pharmacol* 2005;21(3):337-340
4. Balint GP, Balint PV. Felty's syndrome. *Best Pract Res Clin Rheumatol* 2004;18(5):631-45
5. Burks EJ, Loughran TP. Pathogenesis of neutropenia in large granular lymphocyte leukemia and felty syndrome. *Blood Reviews* 2006;20:245-66
6. Rindfleisch JA, Muller D. Diagnosis and management of rheumatoid arthritis. *Am Fam Physician* 2005;72:1037-47
7. Mahevas M, Audia S, De Lastours V, et al. Neutropenia in felty's syndrome successfully treated with hydroxychloroquine. *Haematologica* 2007;92:78-79
8. Lisowska B, Rutkowska-Sak L, Maldyk P, Cwiek R. Anaesthesiological problems in patients with rheumatoid arthritis undergoing orthopaedic surgeries. *Clin Rheumatol* 2008;27:553-56
9. Fombon FN, Thompson JP. Anesthesia for the adult patient with rheumatoid arthritis. *Continuing Education in Anaesthesia, Critical Care & Pain* 2006;6(6):235-39
10. Tanaka M, Balki M, McLeod A, Carvalho J. Regional anesthesia and

non-preeclamptic thrombocytopenia: time to re-think the safe platelet count. *Rev Bras Anesthesiol* 2009;59(2):142-53

11. Frenk V, Camann W, Shankar KB. Regional anesthesia in parturients. *Can J Anaesth* 2005;52(1):114
12. Horlocker T, Wedel D. Regional anesthesia in the immunocompromised patient. *Reg Anesth Pain Med* 2006;31(4):334-45

13. Lundstrom LH, Moller AM, Rosenstock C, et al. A documented previous difficult tracheal intubation as a prognostic test for a subsequent difficult tracheal intubation in adults. *Anaesthesia* 2009;64(10):1081-8

**Mentor:** Terrie Norris, CRNA, EdD

### **Anesthesia for Maxillomandibular Fixation**

Christopher D. Kyle, BSN  
Georgetown University

**Keywords:** Mandibular fracture, Maxillomandibular fixation, Nasopharyngeal dilation, Nasotracheal intubation, Airway patency

Maintaining airway patency is one of the primary goals for the anesthesia professional. Mandibular surgery provides several challenges that impact this goal, including a possible need for nasotracheal intubation, the presence of blood in the airway, difficult access to the airway during surgery, and post-surgical maxillomandibular fixation using wires.<sup>1</sup> Upon emergence and extubation from anesthesia, the anesthesia professional must be confident that the patient will independently maintain a patent airway, avoid aspiration, and maintain appropriate minute ventilation.

#### **Case report**

A 64 kg, 24 year old male presented for repair of a mandibular fracture caused by blunt force trauma. The patient's medical and surgical history was unremarkable, and he denied prior postoperative anesthesia complications. Preoperative medications

included clindamycin and oxycodone/APAP, administered secondary to the fracture. He denied any allergies, and baseline vital signs and laboratory values were normal. The patient had nothing by mouth during the previous 12 hours. Preoperative physical exam revealed facial pain, associated maxillomandibular swelling, limited range of neck extension, limited head rotation, and difficulty opening the mouth. Mouth opening was limited to 2 fingerbreadths, and revealed a Mallampati 4 classification with all teeth intact. There were no battle's signs nor fluid discharge from the ears or nose.

In the preoperative holding area, an intravenous (IV) crystalloid infusion was started. After administering midazolam 2 mg IV and dexamethasone 10mg IV, the patient was taken to the operating room (OR). Standard monitors were applied, and cocaine 4% pledgets were placed in each of the patient's nares. After 5 minutes, the cocaine pledgets were removed, and each nare sprayed with 0.3 mL of oxymetazoline 0.05%. The patient was preoxygenated with 10 L/minute via facemask, and propofol 200 mg IV was administered to induce general

anesthesia. After verifying apnea, the patient was manually ventilated and rocuronium was administered to provide muscle relaxation. An additional 3 mg of midazolam was given, followed by fentanyl 100 mcg IV. The patient's left nostril was sequentially dilated with 28, 30, and 32 French nasopharyngeal airways in order to facilitate nasotracheal intubation. Direct visual laryngoscopy was performed with a Macintosh #4 blade and revealed a Grade I view. Magill forceps were used to guide a 7.0 mm reinforced endotracheal tube (ETT) from the oropharynx through the vocal cords. The ETT was inflated with 7 mL of air, and confirmation of placement was verified by the presence of CO<sub>2</sub>, auscultation of all lung fields, and vapor exchange within the ETT. Sevoflurane was initiated for the maintenance of general anesthesia, and additional IV fentanyl was titrated as needed.

A nasogastric tube (NGT) was placed by the surgeon prior to maxillomandibular fixation and removed after fixation was complete and secretions cleared. Upon completion of the surgery and verification of 2/4 twitches with a peripheral nerve stimulator, neostigmine 4 mg IV and glycopyrrolate 0.8 mg IV were administered. Ondansetron 4 mg IV was also given. Extubation did not occur until 4/4 twitches were verified, and only after the patient was fully awake, following commands, and demonstrating adequate ventilations by maintaining SpO<sub>2</sub> > 90% and EtCO<sub>2</sub> < 50 mmHg. Internal maxillomandibular fixation was in place upon extubation, and the patient maintained a patent airway without any acute events throughout the remainder of his hospital stay.

## Discussion

Nasotracheal intubation may be indicated in cases involving the lower 1/3<sup>rd</sup> of the face or

mouth, and when maxillomandibular fixation is planned.<sup>2</sup> Each patient needs a complete airway and physical assessment prior to nasotracheal intubation, as facial or cribiform plate trauma may require an awake fiberoptic oral intubation, a tracheotomy, or submental intubation. Due to this patient having limited mouth opening and a Mallampati 4 classification, fiberoptic equipment was available. Once paralysis was established, however, both mouth opening and oral visualization improved. In general, if a patient presents with a Battle sign or blepharon hematoma, nasotracheal intubation is not preferred.<sup>3</sup> Surgical consultation is recommended to formulate the safest and most efficacious airway plan. During cases requiring nasotracheal intubation, the anesthesia professional must carefully assess each nare for clearance viability. This can be done by asking the patient to breathe through each nostril independently in order to compare bilateral airflow, by examining radiographic data, and through consultation with the surgeon. Once ETT placement is verified, it should be sutured by the surgeon in a manner that securely positions the tube while concurrently preventing local tissue ischemia.

The most common complication of nasotracheal intubation is nasal mucosal trauma and hemorrhage.<sup>4</sup> It may be necessary to examine the patient's coagulation values, complete blood count, and liver function tests in order to ascertain bleeding risks. The prophylactic use of steroids may reduce mucosal swelling. The use of local vasoconstrictors, or incremental mechanical dilation of the nasopharyngeal airways, may reduce the occurrence of bleeding.<sup>4</sup> Patients with cardiac risk factors, however, should be carefully screened before receiving topical cocaine, oxymetazoline, or phenylephrine.<sup>5</sup> These are

potent alpha<sub>1</sub> adrenergic agonists, and may cause hypertension with rebound bradycardia, an especially harmful concern for pediatric patients.<sup>6</sup> Cocaine pledgets were used in this case, and administered prior to induction per surgeon request, yet placement following induction may prevent patient discomfort and associated anxiety.

Following maxillomandibular fixation, the anesthesia professional will no longer have direct oropharyngeal visualization. It is important that postoperative nausea and vomiting be minimized. If suctioning is required, blind nasopharyngeal suctioning or fiberoptic devices may be required. It is important to note that the risk of aspiration may be increased following the use of topical local anesthetics in the nasal mucosa, especially in those patients already at risk for a full stomach.<sup>2</sup> In this case, the patient had not eaten for 12 hours prior to surgery, and IV hydration, dexamethasone and ondansetron were administered. No prokinetics, antacids, or histamine receptor blockers were administered; however, the efficacy of these measures should be considered on a case to case basis.<sup>7</sup> An NGT was inserted and should be considered in order to empty gastric contents and to minimize aspiration risks.

The sympathetic pain response should be minimized in order to prevent gastroparesis. Opiates should be judiciously administered, however, so that nausea and postoperative respiratory depression are minimized. The use of regional anesthetics may reduce the need for perioperative opiate administration.<sup>8</sup> In this case, the surgeon opted against local anesthetic injections. A total of 300 mcg of fentanyl was given and proved effective; the patient awoke without nausea or vomiting and with minimal pain.

Emergence should be smooth and

uneventful. In this case, fentanyl was titrated to maintain a respiratory rate of < 12-14, and the OR was quiet with the patient normothermic and minimally stimulated. During extubation, it is imperative that airway reflexes remain intact, and that the patient remain strong and awake to protect the airway. Administration of succinylcholine may be a prudent choice for induction, to minimize prolonged paralysis and to assess the function of facial nerves, if surgically indicated. Due to the expected length of this case, and the general consensus that this patient's Mallampati 4 classification would greatly improve once relaxed and sedated, rocuronium was chosen and proved effective. Fiberoptic equipment was also available in the case that direct visual laryngoscopy failed. Regardless of choice, paralysis needs to be fully reversed, and the patient should meet all preestablished extubation criteria. If there is uncertainty regarding the safety of extubation, it may be better to keep the patient intubated until later assessments yield more confident results. The surgeon should remain available during extubation, ready to quickly cut and remove the maxillomandibular wiring if necessary. Fiberoptic equipment should be readily available if reintubation is required. In the post-anesthesia care unit, wire cutters should be readily available and taken with the patient during discharge home.

The use of maxillomandibular fixation during surgery provides challenges for the anesthesia professional, but these challenges can be overcome with careful planning and vigilance. A key component to the safe anesthetic management of these patients includes a complete preoperative assessment. Bleeding risks should be evaluated, and local vasoconstrictors or gentle nasopharyngeal dilation should be utilized when needed. It is important to

minimize perioperative nausea and vomiting, to avoid aspiration, and to maintain a patent airway by extubating the patient when fully awake, following commands, and fully reversed from the neuromuscular blockade. Emergence should be controlled, smooth, and uneventful. Finally, the anesthesia professional should consult with the surgical team and formulate an individual plan for each patient, one that provides the safest and most efficacious outcome.

## References

1. Donlon JV, Doyle DJ, Feldman MA. Anesthesia for eye, ear, nose, and throat surgery. In Miller RD, ed. *Miller's Anesthesia*. 6<sup>th</sup> ed. Philadelphia: Churchill Livingstone; 2005:2527-2555.
2. Krohner RG. Anesthetic considerations and techniques for oral and maxillofacial surgery. *Int Anesthesiol Clin*. 2003;41:67-89.
3. Lee SS, Huang SH, Wu SH, et al. A review of intraoperative airway management for midface facial bone fracture patients. *Ann Plast Surg*. 2009;63:162-166.
4. Hall CE, Shutt LE. Nasotracheal intubation for head and neck surgery. *Anaesthesia*. 2003;58:249-256.
5. Makaryus JN, Makaryus AN, Johnson M. Acute myocardial infarction following the use of anesthetic cocaine. *South Med J*. 2006;99:759-761.
6. Thrush DN. Cardiac arrest after oxymetazoline nasal spray. *J Clin Anesth*. 1995;7:512-514.
7. Ng A, Smith, G. Gastroesophageal reflux and aspiration of gastric contents in anesthesia practice. *Anesth Analg*. 2001;93:494-513.
8. White PF. The changing role of non-opioid analgesic techniques in the management of postoperative pain. *Anesth Analg*. 2005;101:S5-S22.

**Mentor:** Denise Tola, CRNA, MSN

## Acute Respiratory Distress Syndrome in the Cardiac Patient

Lyndsay A. Bikul, MS  
Kaiser Permanente School of Anesthesia

**Keywords:** acute respiratory distress syndrome; cardiac surgery; anesthesia

Acute respiratory distress syndrome (ARDS) is an acute inflammatory process from a direct lung injury resulting in alveolar damage and increased alveolar permeability. Eventually, this process can lead to hypoxemia and respiratory failure.<sup>1</sup> Management is aimed at optimizing respiratory function and preventing further insult to all organ systems. Cardiac surgery patients with ARDS pose an even greater challenge. The effect of cardiopulmonary

bypass (CPB) creates an inflammatory process throughout the body and when combined with an already compromised patient, the effects are magnified. The purpose of this case study is to discuss the anesthetic management of a patient with ARDS undergoing cardiac surgery.

### Case Report

A 68-year-old male patient, American Society of Anesthesiologists (ASA) physical status 4, was scheduled for a coronary artery bypass graft (CABG) with a mitral valve

replacement. The patient had a previous medical history of coronary artery disease and mitral valve stenosis. Co-morbidities included: hyperlipidemia, hypertension and diabetes mellitus. The patient was 178 centimeters tall and weighed 85 kilograms and denied having allergies to medication. After the surgery, the patient developed septic shock and was subsequently reintubated and supported on vasopressors, steroids and antibiotics. After four days, the patient demonstrated signs of improvement, was extubated and was discharged home after an otherwise unremarkable hospital course. Home medications included atenolol, simvastatin, lisinopril, coumadin and insulin.

Ten days after his discharge, the patient was re-admitted for cardiogenic shock requiring endotracheal intubation, mechanical ventilation and vasopressor therapy. During the course of this admission, the patient aspirated his tube feedings sustaining aspiration pneumonitis. A chest x-ray (CXR) revealed the presence of diffuse, bilateral infiltrates. The patient became increasingly difficult to ventilate. Serial arterial blood gases (ABG) revealed severe hypoxemia despite ventilatory support with 100% inspired oxygen. Physical examination revealed diminished lung sounds in all fields and crackles could be appreciated bilaterally. The diagnosis of ARDS was confirmed.

Through coronary angiography, the cardiac surgeon determined the patient's cardiogenic shock was the result of a premature coronary graft closure. Laboratory findings were: prothrombin time (PT) 15 seconds, partial prothrombin time (PTT) 34 seconds and international normalized ratio (INR) 1.1. It was hypothesized that the grafts closed due to the combination of poor bypass targets coupled with medication non-compliance

evidenced by the patient's low INR. It was also documented that the patient missed follow-up appointments for INR monitoring. The cardiac surgical team decided to perform a redo CABG without cardiopulmonary bypass (CPB) to add an additional bypass vein graft.

The patient was brought to the operating room (OR) already intubated from the intensive care unit (ICU), therefore re-intubation was not required. An arterial line and introducer with a Swan-Ganz catheter were in place. Anesthesia was initiated using a balanced technique consisting of low volatile isoflurane, pancuronium and fentanyl.

The presence of ARDS required adjustment of the ventilator settings to maintain adequate oxygenation. Low tidal volumes of 5-6 mL/kg were administered using a pressure regulated volume controlled mode. An inverse inspiratory expiratory ratio of three to one and a positive end-expiratory pressure (PEEP) of 5 cmH<sub>2</sub>O was applied. The patient's oxygen saturation (SpO<sub>2</sub>) was maintained at or above 92%. A milrinone infusion was initiated to manage the increasing pulmonary artery pressures. A conservative fluid schedule was maintained to prevent pulmonary overload. Filling pressures were monitored via the pulmonary catheter. Urinary output was maintained at 1 ml/kg/hr.

The patient tolerated the procedure and was transferred to the ICU intubated and on milrinone, vasopressin, epinephrine and dopamine infusions. Postoperative orders included maintaining intraoperative ventilatory settings. Sedation was continued with fentanyl and midazolam infusions for postoperative patient comfort.

Post-operatively the patient required prolonged mechanical ventilatory support and received a tracheostomy on post-op day 10. He was subsequently weaned from the ventilator and discharged to an acute care rehabilitation facility on post-op day 25.

## Discussion

ARDS was previously known as adult respiratory distress syndrome. The definition was changed to acute respiratory distress syndrome to include pediatric patients who were also affected. The American-European Consensus Conference Committee based the definition of ARDS on the following criteria: acute onset, bilateral infiltrates on CXR, pulmonary artery wedge pressure (PAWP) of less than or equal to 18 mmHg, absence of clinical evidence of left atrial hypertrophy, and a ratio of the partial pressure of arterial oxygen ( $\text{PaO}_2$ ) and fraction of inspired oxygen ( $\text{FiO}_2$ ) less than 200.<sup>2</sup> ARDS is typically the result of a direct or indirect lung injury.<sup>3</sup> In this case study, the patient aspirated his tube feedings, thus precipitating direct lung injury.

Cardiac patients with ARDS present a challenge to both the anesthesia and the cardiac surgery teams. Cardiopulmonary bypass presents increased risk of complications, including an acute systemic inflammatory reaction leading to post-operative pulmonary complications.<sup>4</sup> When combined with CPB, the depressive effects of general anesthesia and cardiac surgery are amplified. Off-pump CABG is associated with a reduction of inflammatory and chemical mediators that contribute to post-operative lung dysfunction.<sup>5</sup> While CPB cannot be implicated as a primary risk factor in the development of ARDS, it should be avoided unless absolutely necessary in patients who present with ARDS.

Anesthetic management of a patient with ARDS requires intubation and mechanical ventilation to maintain adequate oxygenation. As a result of hypoxemia and hypercapnia due to cardiogenic shock, this patient was already intubated. Careful adjustment of the ventilator settings was required to prevent hypoventilation, hypoxia and barotrauma. Different strategies to recruit alveoli such as low tidal volumes, inverse-ratio ventilation, and PEEP have demonstrated to be effective in the patient with ARDS. These techniques were initiated in the ICU after the diagnosis of ARDS was made and continued through the perioperative period.

Conventional tidal volumes typically range from 8 - 10 mL/kg. However, in the presence of ARDS lower tidal volumes less than 6 mL/kg are used to provide protective ventilation.<sup>6</sup> In order to evaluate the effectiveness of this strategy, plateau pressures were measured. Low tidal volumes created plateau pressures equal to or less than 30 cmH<sub>2</sub>O, a pressure not likely to cause barotrauma.<sup>6</sup> Studies have demonstrated decreased incidence of barotrauma and greater success of weaning from the ventilator when smaller tidal volumes were used.<sup>6</sup> It is worth mentioning that the respiratory rate often has to be increased to prevent hypercapnia and subsequent acidemia as a result of low tidal volumes.

Positive end-expiratory pressure is commonly employed in the presence of refractory hypoxemia allowing the alveoli to remain open at end-expiration. As the alveoli remain open, ventilation and perfusion is optimized. Positive end expiratory pressure is used in conjunction with a lower  $\text{FiO}_2$  to avoid oxygen toxicity.<sup>6</sup> Current recommendations suggest using the least amount of PEEP required to maintain oxygenation.<sup>6</sup> Excessive use of PEEP can



interfere with venous return thereby decreasing cardiac output. It is prudent to maintain PEEP at or below 15 cm of water pressure.<sup>7</sup> Another method to improve oxygenation without increasing PEEP is implementing an inverse inspiratory-expiratory ratio. This technique promotes more time in inspiration, allowing the alveoli to remain open longer and provides increased time for O<sub>2</sub> diffusion into the blood.

In addition to ensuring adequate oxygenation, intravascular fluid volume must also be maintained. The goal in fluid management is to prevent end-organ damage as the result of hypoperfusion.<sup>8</sup> The conundrum in this situation is the balance between too much and too little fluid replacement. Current recommendations support conservative fluid replacement to maintain organ perfusion, while decreasing pulmonary overload and reducing the duration of mechanical ventilation.<sup>9</sup> This method utilizes minimal fluid intake and increased diuresis. Volume status is assessed using a pulmonary artery catheter to measure filling pressures within the heart.<sup>8</sup>

This case report describes the management of a cardiac surgical patient with ARDS. Alveolar recruitment strategies that have proven to be beneficial in the outcome of ARDS patients were implemented. Additionally, a conservative method to fluid resuscitation was used to reduce the risk of lung injury. The patient was supported on milrinone, vasopressin, epinephrine and dopamine infusions to ensure organ perfusion and cardiac function. As a result of well developed anesthetic plan, further insult to the patient was minimized and the patient had a successful outcome.

## References

1. Treggiari MM, Deem S. Anesthesia and critical care medicine. In: Barash PG, Cullen, BF, Stoelting RK eds. *Clinical Anesthesia*. 5<sup>th</sup> ed. Philadelphia, PA: Lippincott Williams & Wilkins; 2006;1484-1486.
2. Bernard GR, Artigas A, Brigham KL, et al. The American-European Consensus Conference on ARDS: definitions, mechanisms, relevant outcomes, and clinical trial coordination. *Am J Respir Crit Care Med*. 1994;149:818-824.
3. Ware LB, Matthay, MA. The acute respiratory distress syndrome. *N Engl J Med*. 2000;324(18):1334-1349.
4. Ng CHS, Wan S, Yim APC, Arifi AA. Pulmonary dysfunction after cardiac surgery. *Chest*. 2002;121:1269-1277.
5. Ascione R, Lloyd CT, Underwood MJ, et al. Inflammatory response after coronary revascularization with or without cardiopulmonary bypass. *Ann Thorac Surg*. 2000; 69:1198–1204.
6. Malhotra A. Low-tidal-volume ventilation in the acute respiratory distress syndrome. *N Engl J Med*. 2009;357(11):1113-1120.
7. Grasso S, Mascia L, Del Turco M, et al. Effects of recruiting maneuvers in patients with acute respiratory distress syndrome ventilated with protective ventilatory strategies. *Anesthesiology* 2002; 96(4):795-802.
8. Rieker M. Respiratory anatomy, physiology, pathophysiology and anesthesia management. In: Nagelhout, JJ, Plaus KL eds. *Nurse Anesthesia*. 4<sup>th</sup> ed. St. Louis, MI: Saunders Elsevier; 2010; 610-612.

9. Weidemann HP, Wheeler AP, Bernard GR, et al. Comparison of two fluid-management strategies in acute lung

injury. *N Engl J Med.* 2006;354(24):2564-2575.

**Mentor:** Edward Waters, CRNA, MN

## Undiagnosed Peripartum Cardiomyopathy

Ashleah Pope, MS  
University of Southern California

**Keywords:** peripartum cardiomyopathy, heart failure, pregnancy complications, anesthesia, anesthetic management

Peripartum cardiomyopathy (PPCM) is a rare form of idiopathic heart failure that occurs in the third trimester until 5 months after delivery. The incidence ranges from 1:3000 to 1:4000 live births.<sup>1</sup> This disease process has the unique ability to elude diagnosis. Many signs of PPCM are expected in the full term parturient such as dyspnea, fatigue, and peripheral edema. The mortality rate is between 0-5%, with most deaths occurring within 3 months after delivery. Mortality is usually due to progressive congestive heart failure, sudden death from arrhythmias, or thromboembolic events.<sup>2</sup>

### Case Report

A 25-year-old, 60 in, 69 kg, gravida 2, para 1, female presented in active labor at 39 weeks. Past medical history was significant for chronic anemia, Hct 30%. She denied any complications with this pregnancy and all other labs within normal limits. Her tuberculosis screening chest x-ray (CXR), a normal procedure at this facility, taken 45 days prior was normal, and there was no prior electrocardiogram (EKG) on file. Her breath sounds were clear to auscultation and heart sounds were distant but negative for murmurs, rubs, or gallops.

The patient was taken to the operating room for an emergent cesarean section (C/S) due to late decelerations after 12 hours of labor. Standard monitors were applied and oxygen delivered at 2 liters/minute (l/min) via nasal cannula. Her epidural was bolused with 2% lidocaine in 5ml increments, 20 ml total. Vital signs remained stable at incision: blood pressure (BP) 102/58 mmHg, heart rate (HR) 89 beats per minute (bpm), oxygen saturation (SpO<sub>2</sub>) 99%. After delivery, oxytocin 60 units was diluted in lactated ringers (LR) 700ml. Within one minute of delivery her SpO<sub>2</sub> dropped to 90%. She was encouraged to take deep breaths and the oxygen was increased incrementally to 15 l/min via simple facemask. After two minutes the SpO<sub>2</sub> increased to 99%. At this time, the BP decreased to 69/49 mmHg and HR increased to 116 bpm. No ST or T wave changes were observed and the patient denied nausea, dyspnea, and diaphoresis. A phenylephrine infusion was initiated at 60 mcg/min and intermittent boluses of 100 mcg were administered without improvement.

Blood loss at this time was 1000 ml and total intravenous fluid administration included colloid 500 ml and LR 500 ml. The surgeons were notified of her change in hemodynamic status and they denied complications such as bleeding or a boggy uterus. The phenylephrine infusion was

titrated up to 100 mcg/min without any improvement in her BP or HR, which remained around 63-74/42-55 mmHg and 92-116 bpm, respectively. An ABG revealed a mild metabolic acidosis with a large alveolar-arterial gradient (A-a), an elevated lactate level at 3.3g/dL; the Hct was 30% with normal electrolytes. The intraoperative CXR demonstrated questionable fluid over the bases. The phenylephrine infusion was discontinued prior to the conclusion of surgery and her BP and HR remained within the same range. Surgery concluded and the patient was taken to the recovery room with no change in level of consciousness and still denying nausea or dyspnea.

Postoperative vital signs were BP 63/38 mmHg, HR 111 bpm, and SpO<sub>2</sub> 98% with oxygen at 8 l/min delivered via facemask. The patient was alert and oriented denying dyspnea, chest pain, nausea, or diaphoresis. The 12-lead EKG revealed sinus tachycardia with ST depression in V4-V6. A troponin T level was sent, which was elevated at 0.33ng/ml. Cardiology was consulted and a transthoracic echocardiogram revealed an ejection fraction (EF) of 35% with left ventricular (LV) dilation and hypokinesis. A nitroglycerine infusion was initiated at 5 mcg/min, which resolved the ST depression and the patient was sent to the cardiac intensive care unit. Cardiac catheterization on postoperative day one was negative for coronary disease and the patient was diagnosed with peripartum cardiomyopathy. Medical management included benazapril, carvedilol, and lasix for diuresis. She was discharged seven days later with an EF of 48% and normal LV wall motion.

## **Discussion**

PPCM involves left ventricular systolic dysfunction in women without history of heart disease and is a diagnosis of exclusion.

The onset is easily masked due to the similarity of symptoms in late pregnancy. Dyspnea can be attributed to elevation of the diaphragm by the growing uterus and hyperventilation secondary to increased progesterone levels. Peripheral edema occurs in approximately two-thirds of healthy pregnant women.<sup>3</sup> Vague symptoms often lead to late diagnoses and increased morbidity and mortality.<sup>4</sup> Signs and symptoms that should raise suspicion of heart failure include new regurgitant murmurs, pulmonary crackles, chest pain, nocturnal cough, and paroxysmal nocturnal dyspnea.<sup>5</sup> Our patient was positive for fatigue, dyspnea, and pedal edema, but it was attributed to being full term; she was otherwise asymptomatic for heart failure. It is essential that anesthesia professionals have a high index of suspicion and a low threshold for echocardiography.

The treatment of PPCM involves fluid and salt restriction and the use of diuretics to minimize pulmonary congestion and fluid overload. Patients with systolic dysfunction are treated with vasodilators for afterload reduction.<sup>5</sup> Hydralazine is the drug of choice during the prenatal period, in addition to nitrates or amlodipine, because of the lack of teratogenicity. Angiotensin-converting enzyme inhibitors are the mainstay of postpartum treatment.<sup>5</sup> Beta-blockade is also recommended as it improves symptoms, ejection fraction, and survival.<sup>3</sup> Care needs to be taken to educate mothers of the side effects of these medications and the possibility of excretion in breast milk.

With afterload reduction being a goal of treatment, the phenylephrine infusion that was used to treat hypotension during our case would be contraindicated. Phenylephrine increases afterload and increases the workload of the heart and can exacerbate symptoms of heart failure. Had a

diagnosis of PPCM been made, phenylephrine would not have been our first choice for the treatment of hypotension. An inotrope with afterload reduction, such as milrinone or dobutamine, would have been beneficial.

The higher risk of thromboembolism during pregnancy is due to a greater concentration of coagulation factors. This risk increases in PPCM and anticoagulation therapy is often warranted.<sup>3</sup> Warfarin is teratogenic and contraindicated during pregnancy but unfractionated heparin or low-molecular-weight heparin can be prescribed.

Pregnancy and delivery produce an increase hemodynamic stress on the heart. The type of delivery should be based on obstetrical indications. Vaginal deliveries with effective pain management are beneficial secondary to minimal blood loss and less chance of pulmonary complications and postoperative infection. Regional anesthesia provides pain relief and prevents further increases in cardiac output from pain and anxiety, in addition to reducing preload and afterload.<sup>5</sup> Cesarean delivery, when indicated, can be done under general or regional anesthesia.

Regardless of which anesthetic technique is selected, maintenance of a low to normal heart rate and normotension will decrease oxygen demands and maximize oxygen supply.<sup>5</sup> The maintenance of normal blood oxygen saturation is also important to maximize oxygen delivery to the tissues and prevent organ dysfunction.<sup>3</sup> In our case, the patient's SpO<sub>2</sub> dropped to 90% after delivery of the fetus, secondary to the drop in cardiac output and V/Q mismatching. Her SpO<sub>2</sub> improved by increasing the fraction of inspired oxygen. However, had the true diagnosis been known, an inotropic agent would have been beneficial in improving her

cardiac output and BP, resulting in improved tissue perfusion and SpO<sub>2</sub>.

In a study of patients with various types of cardiomyopathy, those with PPCM had a substantially better prognosis with a 94% survival rate at 5 years.<sup>3</sup> Prognosis is improved in those with an EF greater than 30% at diagnosis but the risk of relapse with subsequent pregnancies still carries a great risk.<sup>3</sup> Patients with recovered LV EF, who can demonstrate a normal LV contractive reserve after a dobutamine challenge, may undertake another pregnancy but still are at increased risk of relapse.

This case was a perfect example of the elusive PPCM diagnosis. We all overlooked the signs of PPCM and attributed them to a normal variant of pregnancy. I learned to always suspect the worse until you have proven otherwise. A simple chest x-ray upon admission or having a high index of suspicion for her symptoms may have prompted additional testing, which could have been the difference between an early diagnosis and exacerbation of heart failure.

## References

1. Longnecker DE, Brown DL, Newman MF, Zapol WM. *Anesthesiology*. New York: McGraw-Hill; 2008:365-6.
2. Hines RL, Marschall KE. *Stoelting's Anesthesia and Co-existing Diseases*. 5<sup>th</sup> ed. Philadelphia: Churchill Livingstone; 2008:120-1.
3. Ramaraj R, Sorrell VL. Peripartum cardiomyopathy: causes, diagnosis, and treatment. *Cleveland Clinic Journal of Medicine*. 2009;76:289-296.
4. Sliwa K, Tibazarwa K, Kleiner DH. Management of peripartum cardiomyopathy. *Current Heart Failure Reports*. 2009;5:238-244.

5. Ray P, Murphy GJ, Shutt LE.  
Recognition and management of

maternal cardiac disease in pregnancy.  
*Br J Anaesth.* 2004;93:428-39.

**Mentor:** Terrie Norris, CRNA, EdD

## Management of the Pediatric Patient with Osteogenesis Imperfecta

Benjamin Lindsey, MS  
University of Southern California

**Keywords:** osteogenesis imperfecta, dental surgery, pediatric anesthesia

Osteogenesis Imperfecta (OI), or brittle bone disease, is an inherited connective tissue disorder characterized by fragile skin, hypermobile joints, skeletal deformities and easily fractured bones.<sup>1</sup> The first documented case of OI was by Willem Vrolik in his Handbook of Pathological Anatomy in 1842.<sup>2</sup> According to the National Institute of Health, it is estimated that OI affects between 20,000 to 50,000 people in the United States.<sup>3</sup> Patients with OI present a unique set of challenges for the anesthesia professional. This case study will discuss the anesthetic management of a 12-year-old patient with OI for tooth extractions.

### Case Summary

A 12-year-old, 28 kg male presented for multiple tooth extractions and crown on tooth number two. Diagnosed with OI at birth, this patient has had multiple orthopedic surgeries to correct fractures and other dental procedures all without anesthetic complications. The patient's preoperative metabolic, complete blood cell count and coagulation panel laboratory results were within normal limits. A preoperative electrocardiogram and echocardiogram were also completed two weeks prior to the case. The patient was in a

normal sinus rhythm and his valvular function and ejection fraction were unremarkable.

A premedication of midazolam 12 mg by mouth was administered 20 minutes prior to the scheduled surgery start time in the preoperative holding room. Padding was placed around all gurney rails and the patient was transported to the operating room. Standard monitors were placed with the exception of a blood pressure cuff.

The patient was given oxygen 7 liters per minute through the anesthesia circuit for three minutes followed by a mixture of oxygen 2 liters per minute and nitrous oxide 5 liters per minute for an additional two minutes. Sevoflurane 2% was initiated and the concentration was increased by 2% every 30 seconds until the patient had lost consciousness. A 22 gauge peripheral IV and a radial arterial line were placed. Vecuronium 2.5 mg and fentanyl 20 mcg were administered and in-line stabilization of the cervical spine from the front was employed for endotracheal intubation. General anesthesia was maintained with sevoflurane, air and oxygen.

Lidocaine 2% with epinephrine 1:200K was injected in the tissue surrounding the teeth to be extracted and the surgery was completed without any difficulties. The total procedure time was 87 minutes. Lactated Ringer's

solution 800 ml was infused during the procedure and the estimated blood loss was minimal. Ondansetron 2 mg was given 20 minutes prior to the conclusion of the surgery and the patient was extubated deep without any complications. The postoperative course was uneventful and the patient was discharged home after 90 minutes in the recovery room.

## Discussion

OI is an autosomal dominant, inherited disease of connective tissue.<sup>4</sup> In a patient with OI, the genes responsible for the creation of type 1 collagen are mutated causing either a weaker version or an insufficient quantity of type 1 collagen.<sup>4,5</sup> Type 1 collagen is the major connective tissue component in bones, ligaments, teeth and the sclera of the eyeball. As such, OI patients will present with a multitude of symptoms including: bone fractures in the absence of trauma, skeletal deformities, mobility impairments, short stature, hearing loss, blue sclera and dentinogenesis imperfecta.<sup>5</sup>

The patient with OI provides unique intraoperative challenges for the anesthesia professional including monitoring and positioning, airway management, the link between OI and malignant hyperthermia (MH), ventilation, cardiac anomalies and bleeding diathesis.<sup>6</sup> The initial concern in the management of the OI patient is monitoring and positioning. The patient in this case was classified with type III (severe) OI, and the risk of causing a fracture by taking a non-invasive blood pressure was extremely high.<sup>4</sup> An intra-arterial catheter was placed to monitor blood pressure prior to intubation. Proper positioning is critical in all cases, but for our patient with OI, special consideration to positioning to prevent overextension and

dislocation, and additional padding of pressure points was imperative to assure bone, joint, neurologic and integumentary safety.<sup>6</sup>

Due to the instability of their cervical spine, the ease at which their teeth are chipped or dislodged and the fragility of their mandible, managing the airway in the patient with OI is a delicate task. Prior case studies have advocated for the use of a laryngeal mask airway (LMA), when appropriate, to protect against cervical-spine, teeth and mandible damage.<sup>7-9</sup> Due to the nature of the surgical procedure, a LMA was not an option for this case. We chose to use in-line stabilization of the cervical spine and a Miller blade to limit the amount of extension and mouth opening required to successfully intubate the trachea. Fiberoptic intubation may decrease the risk of tooth and mandibular damage that could occur with a direct laryngoscopy and would have been an appropriate alternative.<sup>4</sup> Succinylcholine should be avoided due to the fasciculations associated with its use.<sup>4</sup>

It has been postulated that a link exists between OI and malignant hyperthermia (MH).<sup>8-10</sup> This belief has led many to avoid MH triggering agents when caring for OI patients. A case was reported of an OI patient developing tachycardia, metabolic acidosis and hyperthermia to 40<sup>0</sup> C following an anesthetic with barbiturates, fentanyl, pancuronium and nitrous oxide.<sup>10</sup> Although none of these drugs are considered triggering agents for MH, the patient was treated for MH and it was later determined through an in vitro contracture test that the hypermetabolism was not due to MH.<sup>10</sup> Hypermetabolism has been shown to exist in patients with OI as evidenced by abnormally low body weights, increases in heart and respiratory rates, oral temperatures and elevated serum thyroxine levels.<sup>11</sup> Many case reports exist of OI patients

experiencing anesthesia-induced tachycardia, metabolic acidosis and hyperthermia but no definitive link has been established to MH.<sup>9</sup> We chose to use sevoflurane for the maintenance of anesthesia. Tachycardia was observed with a maximum heart rate of 154 but the patient remained normothermic at 36.7° C throughout the procedure. Although the patient's end tidal carbon dioxide level remained normal throughout the procedure, a preinduction and postoperative arterial blood gas sample might have been valuable in assessing the impact of anesthesia on the patient's metabolism.

Patients with OI often have kyphoscoliosis causing a restrictive ventilation pattern and ventilation-perfusion mismatching.<sup>4</sup> Preoxygenation with 1.0 FiO<sub>2</sub> and a rapid intubation will decrease the likelihood the patient will desaturate with induction. Intra-operatively, the patient may require a higher FiO<sub>2</sub> and PEEP to maintain adequate oxygenation during the procedure although this was not necessary during this case.

Impaired platelet function, decreased levels of factor VIII and increased capillary fragility can occur in patients with OI.<sup>12</sup> Previous cases have been described of patients with OI experiencing diffuse intra-operative bleeding secondary to marked vascularity and friability of the vessels.<sup>12</sup> Although bleeding may occur despite normal coagulation function tests, a thorough evaluation of pre-operative coagulation studies and bleeding times should be performed prior to surgery.<sup>12</sup> The patient in this case had a full coagulation panel and complete blood cell count drawn and all values were within normal limits and the estimated blood loss was minimal.

OI patients are at increased risk for valve disorders and aortic root dissection.<sup>5</sup> Aortic

insufficiency is the most common defect followed by mitral regurgitation with the pathology appearing almost exclusively to the left side of the heart.<sup>13</sup> It has been recommended that patients with type III OI have an electrocardiogram and an echocardiogram every two years to evaluate cardiac and valvular function.<sup>14</sup> Our patient had an echocardiogram and ECG performed two weeks prior to surgery. The echocardiogram revealed mild mitral regurgitation but both studies were otherwise unremarkable.

Although rare, patients with OI may present to the operating room for a variety of surgical procedures. This case reinforced the importance of adaptability when working with the pediatric population as well as the importance of customizing the anesthetic to the specific needs of the patient. A thorough understanding of the OI patient's unique monitoring, metabolic, cardiovascular and airway challenges will ensure a safe and effective anesthetic and improved patient outcomes.

## References

1. Oakley I, Reece LP. Anesthetic implications for the patient with osteogenesis imperfecta. *AANA Journal*. 2010;78(1):47-53.
2. Baliet B. Aspects of the history of osteogenesis imperfecta (Vrolik's syndrome). *Ann Anat*. 2002;184(1):1-7.
3. Osteogenesis Imperfecta. National Institute of Health. [http://www.niams.nih.gov/Health\\_Info/one/Osteogenesis\\_Imperfecta/default.asp#b](http://www.niams.nih.gov/Health_Info/one/Osteogenesis_Imperfecta/default.asp#b) Accessed May 25, 2010.
4. Schwartz JJ. Skin and musculoskeletal diseases. In: Hines RL, Marschall KE, eds. *Anesthesia and co-existing disease*. 5<sup>th</sup> ed. Philadelphia, PA:Churchill Livingstone; 2008:465.

5. Byers PH, Steiner RD, Pepin MG. Osteogenesis imperfecta. Gene Reviews. <http://www.ncbi.nlm.nih.gov/bookshelf/br.fcgi?book=gene&part=oi> Accessed May 27, 2010
6. Libman RH. Anesthetic considerations for the patient with osteogenesis imperfecta. *Clin Orthop Relat Res.* 1981;159:123-125.
7. Karabiyik L, Capan Z. Osteogenesis imperfecta; different anaesthetic approaches to two paediatric cases. *Pediatric Anesthesia.* 2004;14(6):524-525.
8. Ogawa S, Okutani R, Suehiro K. Anesthetic management using total intravenous anesthesia with remifentanyl in a child with osteogenesis imperfecta. *J Anesth.* 2009;23:123-125.
9. Porsborg P, Astrup G, Bendixen D, Lund AM, Ording H. Osteogenesis imperfecta and malignant hyperthermia: Is there a relationship? *Anaesthesia.* 1996;51(9):863-5
10. Gerd J, Cropp A and Myers DN. Physiological evidence of hypermetabolism in osteogenesis imperfecta. *Pediatrics.* 1972;49:375-391.
11. Keegan, MT, Whatcott, BD, Harrison BA. Osteogenesis Imperfecta, Perioperative Bleeding, and Desmopressin. *Anesthesiology.* 2002;97:1011-1013
12. Wong RS, Fabrizio FM, Shively BK, Wernly JA. Osteogenesis Imperfecta and Cardiovascular Diseases. *Ann Thorac Surg.* 1995;60:1439-1443.
13. Vetter U, Maierhofer B, Muller M, et al. Osteogenesis imperfecta in childhood: cardiac and renal manifestations. *Eur J Pediatr.* 1989;149:184.

**Mentor:** Michele E. Gold, CRNA, PhD

### **Mitochondrial Myopathy: Designing an Anesthetic Plan**

Kathryn W. Phares, BSN  
Wake Forest University Baptist Medical Center,  
University of North Carolina at Greensboro

**Keywords:** mitochondria, myopathy, neuromuscular disorder, anesthesia, bioenergy

Mitochondria generate the energy necessary for normal physiological cellular function, sense oxidative stress and ultimately play a part in apoptosis, or cell death. It is estimated that one in 4,000 people have some form of a genetic-based or acquired mitochondrial disorder.<sup>1</sup> In fact, it has been suggested that diabetes, neurodegenerative disorders, and cardiovascular disease may be rooted in mitochondrial defects.<sup>2</sup> Thus, the implications of the role of mitochondria in

disease processes are particularly relevant to anesthesia practitioners as they develop and carry out appropriate anesthetic plans for patients with diagnosed mitochondrial myopathy.

#### **Case Report**

The patient was a 62 kg, 141cm, 51 year-old female, who reported severe pain in her left leg for one year. She was wheelchair-bound and described numbness, tingling, and subjective weakness of the leg. An MRI scan revealed a large left L5-S1 disc herniation requiring a microendoscopic



discectomy. Her past medical history included mitochondrial myopathy with related balance difficulty, dystonia, generalized weakness, chronic shortness of breath (SOB) requiring oxygen supplementation at night, and speech and vision problems. In addition to mitochondrial myopathy, her history also included hypertension, gastroesophageal reflux disease (GERD), chronic constipation, chronic urinary urgency, hypothyroidism, smoking and left leg pain. The patient's past surgical history included a left L5-S1 microendoscopic discectomy in 2007 with no anesthetic complications. The patient had no known allergies to foods or medications and all lab tests results were within normal limits.

The patient was identified in the holding room. A physical assessment revealed decreased breath sounds in bilateral lower lobes, as well as weakness, numbness and tingling in the left leg with a reported pain scale of 9/10. Fentanyl 25 mcg IV was administered. Airway assessment revealed a Mallampati class 2 airway, thyromental distance of 6cm, oral aperture of 4cm, and limited neck range of motion. The anesthesia and surgical team involved in the patient's case discussed her medical history and developed a plan for deep volatile anesthesia without the use of paralytics.

The patient was transferred to the OR, and assisted to the surgical table in the supine position. Standard monitors were applied, and the patient was pre-oxygenated with 100% oxygen. An uneventful IV induction followed with alfentanil 1.5 mg IV, lidocaine 100 mg IV, and propofol 160 mg IV. The patient was easy to mask ventilate, the trachea was intubated and respirations were controlled by a mechanical ventilator. An esophageal temperature probe was placed to monitor body temperature.

Alfentanil 1mg IV and propofol 30 mg IV were administered and the patient was turned prone and positioned into an Andrews frame. A forced air warmer was applied to the patient's upper body. Anesthesia was maintained with desflurane 5.4%, nitrous oxide, oxygen, and a remifentanyl infusion.

The procedure was uneventful. Throughout the case, the patient received normal saline 500 mL and lactated ringers 1000 mL IV, and blood loss was estimated at 175 mL. The patient demonstrated a respiratory rate of 12 breaths per minute and tidal volume of 425 mL and was following commands; the endotracheal tube was removed and she was transferred to the post anesthesia care unit on supplemental O<sub>2</sub> without complications.

## **Discussion**

Mitochondrial myopathies are a group of disorders affecting the metabolism of skeletal muscle and other high energy organ groups like the heart, brain, eyes, liver and kidneys.<sup>1</sup> This defect interferes with mitochondrial completion of oxidative phosphorylation resulting in depletion of adenosine triphosphate (ATP), which leads to fatigue, muscle pain, progressive weakness, and raised lactic acid levels.<sup>1,3</sup> In reference to the described case, the patient had symptoms related to skeletal muscle weakness and fatigue, respiratory muscle weakness, and swallowing and vision difficulty.

Since these patients are predisposed to metabolic dysfunction and decreased respiratory and cardiac reserves, the patient with mitochondrial myopathy requires prior planning among the anesthesia and surgical team members.<sup>1</sup> Recommendations for anesthesia practitioners include expecting the need for supportive care to avoid

ventilator and circulatory deficiency, possible hepatorenal insufficiency, as well as measures to prevent metabolic acidosis.<sup>2,3,4</sup> Monitoring of body temperature, electrocardiogram, and blood pressure are crucial, and arterial catheterization may be indicated for frequent blood glucose and acid-base monitoring. Patients with mitochondrial myopathy should not fast for long periods due to their poor energy production state; NPO guidelines may render them weaker and fatigued. Fluid management should be carefully managed, concentrating on maintaining blood glucose and avoiding acid-base imbalance.<sup>1,2</sup> For this reason, normal saline or a slow infusing glucose solution, with frequent blood glucose monitoring is often chosen over Ringer's lactate solution (LR), due to its association with an increased lactate load.<sup>2</sup> Furthermore, with possible impaired hepatorenal reserve, the pharmacokinetics of intravenous anesthesia drugs and anesthetic agents may result in delayed recovery.<sup>2</sup> Thus, it is prudent to evaluate hepatic and renal function prior to delivery of any medications for these patients.

It is also important to consider how anesthetic agents affect the mitochondria. Mitochondria are a target for virtually all anesthetic agents, depressing the electron transport chain of the organelle and reducing its energy production capacity.<sup>5</sup> This can be manifested in the form of myocardial protection by inhalation agents, but toxic effects have also been observed. Specifically, propofol has produced refractory cardiac failure, metabolic acidosis and fever in children with mitochondrial myopathy.<sup>1,5</sup> Barbiturates have demonstrated similar effects. Local anesthetics have also been shown to significantly impair oxidative phosphorylation and diminish the bioenergetic capacity of mitochondria.<sup>1,5,6</sup> For this reason, many practitioners would

not have used lidocaine during induction as in this case; however, the benefit of lidocaine for an intubation without muscle relaxation was felt to override potential detriments. Hence, while inhibiting ATP production does not appear to be the mode of action producing anesthesia for anesthetic drugs, it is important to consider that these substances may impair overall function of the mitochondria.

Because mitochondrial abnormalities are often undiagnosed, patients with unidentified mitochondrial myopathies have likely been exposed to varied anesthetics without overt adverse outcomes. Determining the safest anesthetic technique can be difficult. There have been reports of intensification of pre-existing muscle weakness when nondepolarizing muscle relaxants are used, causing concern about extubation at the end of the procedure.<sup>2</sup> Similarly, maintaining spontaneous respirations without a secure airway may result in metabolic exhaustion and eventual airway obstruction.<sup>2</sup> Therefore, conventional wisdom recommends utilization of positive pressure mechanical ventilation to minimize intra- and postoperative ventilatory failure.<sup>2,4</sup> Because of the paucity of evidence regarding further recommendations and observations, a truly evidence-based anesthetic plan is quite difficult.

This anesthetic plan was designed around maintaining adequate ventilation perioperatively with the intention of extubating the patient at the end of surgery. Since the anesthesia team was uncertain how paralytics would affect her pre-existing ventilatory weaknesses, avoiding neuromuscular blocking agents altogether was a logical decision despite the surgical location near the spinal cord. In addition, positive pressure ventilation via an

endotracheal tube was the safest option for the patient in light of her impaired respiratory musculature and prone positioning. Finally, lactated ringers solution was used in lieu of the preferred normal saline and regular evaluation of the patient's glucose and liver function were not included her plan. Thus, while it appeared that the patient adequately tolerated the anesthetic and procedure, the anesthesia team cannot be certain that she did not sustain adverse outcomes related to acid-base imbalance, hypoglycemia, prolonged anesthetic metabolism or mitochondrial depression.

This case serves to remind anesthesia practitioners that they will encounter patients with uncommon diseases or comorbidities. In this setting, there may be very little time for research prior to administering anesthesia. It is therefore important to understand the role of the mitochondria in energy production and appreciate the anesthetic implications surrounding the care of these patients.

## References

1. Driessen, J. Neuromuscular and mitochondrial disorders: what is relevant to the anaesthesiologist? *Curr Opin Anaesthesiol.* 2008;21:350-355
2. Muravchick S, Levy R. Clinical implications of mitochondrial dysfunction. *Anesthesiology.* 2006;105:819-837.
3. Stoelting, RK. 2008. Anesthesia and Co-Existing Disease. 5<sup>th</sup> ed. Saunders.
4. Yuan N, El-Sayed Y, Rouss S., Riley E, Enns G, Robinson T. Successful pregnancy and cesarean delivery via noninvasive ventilation in mitochondrial myopathy. *J Perinatol.* 2009;29:166-167.
5. Muravchick S. 2008 Clinical Implications of mitochondrial disease. *Adv Drug Deliv Rev.* 2008;60:1553-1560.
6. Sokoll MD, Gergis SD. The physiology and pathophysiology of the myoneural junction. *AANA J.* 1982: 33-41.

**Mentor:** Joseph Joyce, CRNA, BS

## Local Anesthesia and Sedation for Knee Arthroscopy

Johnny K. Cheng, MSN  
University of Southern California

**Keywords:** local anesthesia, sedation, knee arthroscopy, midazolam, propofol.

Knee arthroscopy is a procedure used to diagnose and treat intraarticular problems, most commonly torn meniscus. However, the procedure is also used for ligament injuries, osteochondral fractures, removal of loose bodies, arthritis, and infections. The use of local anesthesia with sedation is not a standard technique for this procedure at most hospitals. The advantages of using

local anesthesia include residual postoperative analgesia with the use of long acting local anesthetics and avoidance of the side effects associated with general anesthesia.<sup>1</sup>

## Case Report

A 15 year old, 73 kg male was scheduled for a right knee arthroscopy with hardware removal. The patient had a two year history of right knee pain and osteochondritis. He

underwent a right knee arthroscopy and right open reduction and internal fixation of his distal femur three months prior, and reported severe post-operative nausea and vomiting following this previous surgery. He was not on any medications and his laboratory results were within normal limits.

Preoperative vital signs included a heart rate of 79 beats/min and blood pressure of 130/72 mmHg. A 20 gauge intravenous (IV) catheter was inserted in the left antecubital fossa and the patient was pre-medicated with midazolam 3 mg.

After transport to the operating room, standard monitors were placed and a simple oxygen face mask was used to deliver oxygen at 6 L/min. An additional 1 mg of midazolam was administered. A bolus dose of propofol 30 mg IV was administered followed by a continuous infusion at 150 mcg/kg/min for approximately 5 minutes until a steady state was reached. The propofol infusion was then titrated between 50-75 mcg/kg/min for a respiratory rate of 8 to 14 breaths/min and purposeful response to repeated surgical stimuli (i.e. administration of local anesthesia, incision, manipulation of joint). Dexamethasone 8 mg IV was administered for nausea prophylaxis.

The patient was placed in a sniffing position and a nasal airway was gently inserted to help facilitate a patent airway. Fentanyl 25 mcg IV was given prior to local anesthetic infiltration by the surgeon, consisting of 25 ml of lidocaine 2 % with epinephrine 1:200,000 and 25 ml of bupivacaine 0.5%. Surgery started approximately ten minutes after the administration of the anesthetic solution. The patient's vital signs remained stable during the insertion of the arthroscope and instruments.

Systolic blood pressure during the procedure remained stable over a range of 95 to 105

mmHg with diastolic pressures ranging from 45 to 50 mmHg. Pulse rate was 70 to 80 beats/minute and oxygen saturation remained at 100% with a respiratory rate never below 8 breaths/min. The patient was comfortable and the surgeon was able to perform an adequate examination and remove the hardware. Ondansetron 4 mg IV was administered for nausea prophylaxis. The patient had no pain, airway obstruction, or any anesthetic complications.

The patient was transported to the post anesthesia care unit (PACU) with oxygen at 6 L/min by face mask, where his vital signs remained stable and he denied nausea or pain and was discharged home after 120 minutes in the post anesthesia care unit.

## **Discussion**

Local anesthesia for knee arthroscopy is a well-documented procedure that offers advantages over other types of anesthesia. This method of anesthesia is a safe, inexpensive, and practical alternative to the use of epidural, spinal, or general anesthesia for outpatient knee arthroscopy. A prospective randomized study by Jacobson and colleagues compared local, spinal, and general anesthesia in 400 patients. The study demonstrated that patients receiving local anesthesia required less postoperative analgesia and had a quicker recovery and shorter total hospital stay, leading to an overall cost savings. Although there were no significant differences in patient satisfaction or expected level of pain between the three groups, 12% of the local anesthesia patients indicated they would have preferred an alternate form of anesthesia.<sup>2,3</sup>

Patients in the above referenced study received only paracetamol, ketorolac, and local anesthetic solution. No other intraoperative medications were allowed.

The injection of local anesthetic solution is uncomfortable and many patients find the operating room and the idea of being awake during surgery anxiety provoking.<sup>1</sup> In the Jacobson study, the authors stated the local anesthesia group may have benefited from supplemental sedation and analgesia which had not been given due to the possible risk of amnesia and increased discharge time.<sup>3</sup> In this case, IV sedation supplemented the local anesthesia given by the surgeon.

The combination of local and IV anesthetic medications for sedation and analgesia is particularly well suited for outpatients undergoing less invasive procedures.<sup>1</sup> An individualized formula of medications are administered during sedation to promote patient comfort, cardiorespiratory stability, optimal surgical conditions, and to prevent recall of unpleasant perioperative events. The goal is to minimize the incidence of side effects seen in general anesthesia such as cardiorespiratory depression, nausea and vomiting, delayed emergence, and dysphoria, while allowing for a rapid and complete recovery.

At the present time, no single inhaled or intravenous drug can provide all the components of anesthesia. Patient comfort is maintained by a combination of medications that act synergistically to reduce the dose requirements of each individual component. A study by Vuyk and associates showed that the combination of midazolam and propofol produced a more rapid recovery and better stress response than the use of propofol alone.<sup>4</sup> However; synergistic interaction of drugs may also extend to the undesirable outcomes such as cardiorespiratory depression.

Midazolam and a propofol infusion were selected for the sedative portion of this case for multiple reasons. Midazolam was used

for its amnestic and anxiolytic properties, which are an important part of a balanced anesthetic technique. This allows the more transient and titratable propofol to be adjusted to provide the desired level of consciousness according to the specific stimulus. Furthermore, midazolam decreases the total propofol requirement and has a central muscle relaxant property that can provide better surgical conditions.<sup>5</sup> The short context-sensitive half-time of propofol, combined with rapid effect-site equilibration, makes this a readily titratable drug for IV sedation. Another desirable effect of propofol is the decreased incidence of postoperative nausea and vomiting, regardless of anesthetic technique.<sup>6</sup>

Injection of local anesthetic solutions is uncomfortable, so fentanyl was administered just prior to the local anesthetic injection. The local anesthetic injection consisted of a 1:1 solution of lidocaine 1% with epinephrine 1:200,000 and 0.5% bupivacaine. Utilizing this mixture provides the rapid onset of lidocaine and the extended duration of bupivacaine. Although the onset of the mixture is in minutes, the peak effect takes approximately 30 minutes. Therefore, it is important to communicate to the surgeons that the local anesthesia infiltrate must dwell for a sufficient amount of time to maximize analgesia before the instruments are inserted and the infiltrate leaks out. Maximizing the effects of the local anesthetic can decrease opioid requirements.

Several factors influenced the decision to choose local anesthesia with sedation for this case. Patient factors included normal anatomy on the airway examination, appropriate weight, no history of esophageal reflux, and a willingness to cooperate with directions from the anesthesia care team. Anti-nausea prophylaxis was utilized and an attempt to avoid medications that cause

nausea was also part of the anesthesia plan. Additional important factors influencing the decision to use a sedation and local anesthetic anesthesia plan include a surgeon known to provide effective local anesthetic infiltration. When used in conjunction with IV anesthetic agents, local anesthetic infiltration is capable of providing a comfortable level of sedation and optimal surgical conditions. Lastly, the surgeon, anesthesia team, and patient had a thorough understanding of the surgical and anesthesia plan and agreed to proceed.

It appears that deep sedation, as used in this case, can produce superior operating conditions and patient satisfaction compared to light sedation used in referenced studies. The surgeon described having excellent operating conditions as demonstrated by the lack of patient movement and the ability to manipulate the extremity. The patient reported satisfaction with the anesthetic and stated he had decreased anxiety, complete amnesia of the procedure, no nausea, and no pain throughout the procedure and in the PACU. Deep sedation poses unique challenges, especially to the anesthetist who is faced with providing a balance between patient comfort and optimal surgical conditions, respiratory control, and maintaining the patient's airway reflexes. A thorough pre-anesthetic examination and evaluation aids in patient selection, while monitoring by a vigilant anesthesia professional helps prevent potential complications.

## References

1. Rego MM, Watcha MF, White PF. The changing role of monitored anesthesia care in the ambulatory setting. *Anesth Analg*. 1997;85:1020-1036.
2. Forssblad M, Jacobson E, Weidenhielm L. Knee arthroscopy with different anesthesia methods: a comparison of efficacy and cost. *Knee Surg Sports Traumatol Arthrosc*. 2004;12: 344-349.
3. Jacobson E, Forssblad M, Rosenberg J, Westman L, Weidenhielm L. Can local anesthesia be recommended for routine use in elective knee arthroscopy? A comparison between local, spinal, and general anesthesia. *Arthroscopy*. 2000;16(2):183-190.
4. Vuyk J, Lichtenbelt BJ, Olofsen E, Van Kleef JW, Dahan A. Mixed-effects modeling of the influence of midazolam on propofol pharmacokinetics. *Anesth Analg*. 2009;108(5): 1522-1530.
5. Padmanabhan U, Leslie K, Eer AS, Maruff P, Silbert BS. Early cognitive impairment after sedation for colonoscopy: The effect of adding midazolam and/or fentanyl to propofol. *Anesth Analg*. 2009;109(5):1448-1455.
6. Stoelting RK, Hillier SC. *Pharmacology & Physiology in Anesthetic Practice*. 4th ed. Philadelphia, PA: Lippincott, Williams & Wilkins; 2006:142-163.

**Mentor:** Teresa Norris, CRNA, EdD

## The Patient with Complex Congenital Heart Malformations

Crystal M. Alber, BSN  
Webster University

**Keywords:** single-ventricle, congenital heart malformations, anesthetic implications

Fontan procedure, Glenn shunt, cardiac catheterization

Single-ventricle physiology can pose a challenge during anesthetic management. Physiologically, the single ventricle has to provide circulation to both the systemic and pulmonary circuits. In order to obtain effective palliation, these patients require a complex series of staged procedures to correct the parallel circulation and redirect pulmonary and systemic blood flow. It is essential that the anesthesia professional fully understand the altered physiology that occurs throughout the complex series of anatomical reconstructions as well as the potential complications that can arise along with the appropriate treatment in order to provide the safest possible anesthetic.

### **Case Report**

A 3-year old, 15.8 kg, 89 cm, ASA IV male presented for a cardiac catheterization under general anesthesia. This procedure was one of many in this child's operative course and was necessary to perform pulmonary artery stenting. This patient presented with a complex series of congenital heart malformations and was staged for extensive anatomical reconstruction. His medical history involved a number of congenital heart defects including dextrocardia, a single ventricle, pulmonary stenosis, patent foramen ovale, patent ductus arteriosus (PDA) and an atrial septal defect. The patient also exhibited congenital asplenia, gastroesophageal reflux disease and had a surgical history which included a diaphragmatic hernia repair, gastric tube placement and removal, a Glenn shunt procedure and multiple diagnostic cardiac catheterizations. Daily medications for this patient included furosemide, omeprazole, and enalapril. A cardiac catheterization was scheduled in preparation for an upcoming Fontan procedure.

A thorough preoperative evaluation was performed. The most significant clinical finding was the patient's baseline SpO<sub>2</sub> of 85% on room air. At rest, this patient was acyanotic. However, any exertion produced a clinically significant cyanotic appearance. All other vital signs were within normal limits and appropriate for the patient's age.

Upon arrival for cardiac catheterization, all noninvasive monitors were applied and the patient was preoxygenated for three minutes. A smooth inhalational induction of anesthesia was performed with sevoflurane and oxygen omitting nitrous oxide. Once an appropriate depth of anesthesia was obtained, a 22 gauge peripheral IV was inserted and fentanyl 25 mcg and rocuronium 10 mg were administered. Tracheal intubation was performed without difficulty and mechanical ventilation initiated. Equal bilateral breath sounds were auscultated and positive end-tidal CO<sub>2</sub> was noted. Cefazolin 375 mg was administered prior to the initiation of the procedure. Adequate neuromuscular blockade was maintained with rocuronium. Sufficient analgesia was obtained with incremental doses of fentanyl.

In order for the cardiologist to assess tissue and vascular oxygenation status, oxygen was administered only during induction and emergence. Fresh gas flow during the procedure was maintained with 2L/min of air and with an end-tidal sevoflurane concentration of approximately 2.6%. During the absence of oxygen administration, the patient's oxygen saturation via pulse oximetry varied from 85-92%. The cardiac catheterization itself was uneventful as the patient remained hemodynamically stable during the successful stenting of the pulmonary artery. Neuromuscular blockade was successfully antagonized with neostigmine 0.75 mg and

glycopyrrolate 0.15 mg. Emergence from anesthesia included a deep extubation in an attempt to avoid coughing, an acute increase in pulmonary vascular resistance (PVR), and/or a potential compromise to the site of hemostasis. The patient was transferred to the recovery unit on oxygen 8 L/min via face mask and remained hemodynamically stable. A non-eventful recovery ensued and the patient remained in the hospital for a 23-hour observation.

## Discussion

Single-ventricle physiology can pose quite a challenge during anesthetic management. The anesthesia practitioner must understand the congenital pathology as well as the degree of palliation as this alone may alter the anesthetic course. Each stage of repair has its own coinciding anesthetic implications.

The discussed patient presented with a reduced SpO<sub>2</sub> of 85% that was well tolerated. Considering the anatomical malformations, this was a typical clinical presentation.<sup>3</sup> Pulmonary blood flow is distributed primarily via the patent ductus arteriosus which is inadequate and results in cyanosis. Physiologically, the single ventricle has to provide circulation to both the systemic and pulmonary circuits. In order to obtain effective palliation, these patients require a complicated series of procedures in order to correct the parallel circulation and redirect pulmonary and systemic blood flow. The overall process of reconstruction must be done overtime and in multiple stages. The final stage of correction, or the Fontan operation, must await the normal postnatal reduction of PVR as an elevated PVR will result in an intolerable elevation in systemic vascular resistance (SVR), decreased pulmonary blood flow, and inadequate cardiac output.<sup>9</sup>

Typically, a 3-stage process is utilized in order for the affected child to adequately tolerate the physiologic changes and coexisting demands. Initial maintenance of pulmonary blood flow is provided by the PDA. It is of utmost importance for the PDA to remain patent until surgical intervention is appropriate. Typically, these patients are treated with prostaglandin E1 to prevent premature closure of the PDA.<sup>4,5,9</sup>

The first stage in repair involves the relief of cyanosis via the creation of a systemic artery-to-pulmonary arterial shunt.<sup>9</sup> Inherent risks associated with this procedure are the ventricle's intolerance to sudden increases in afterload and its marked dependence upon preload.<sup>9</sup> These patients can exhibit increasing hypoxemia which can preclude a distinct elevated hematocrit or other alterations in coagulation status which can increase afterload and predispose to thrombosis and its' innate complications.<sup>5,9</sup> Also, a potential rise in PVR will more significantly decrease pulmonary perfusion if hypovolemia is present. Dehydration is a critical risk to these patients and preoperative fasting must be kept to a minimum with adequate intravenous hydration in the interim. Another notable complication is the increased risk for emboli as any air bubble or clot can cause a devastating consequence.<sup>3-5</sup>

The patient's unique anatomic presentation did not allow for the first stage of repair and initial surgical intervention involved the second-stage of palliation. When performed as the initial avenue of repair, the second stage, which is referred to as the Glenn procedure, is an alternate to exposing the pulmonary circulation to the increased systemic pressure that is inevitable with the initial approach (arterial-to-pulmonary shunt).<sup>4</sup> During the Glenn procedure, blood flow from the superior vena cava is



redirected to the right pulmonary artery. This procedure does not fully correct the cyanosis as the inferior vena cava still perfuses systemic circulation.<sup>4</sup> Cyanosis was apparent throughout the discussed cardiac catheterization. Anesthetic management for the patient undergoing the second stage of repair is similar to the first and focused on the balance between PVR and SVR. It is important to maintain a deep level of anesthesia and avoid sympathetic stimulation as this can acutely elevate PVR causing desaturation secondary to inadequate pulmonary blood flow.<sup>1,3,5,9</sup> Opioids and anxiolytics are recommended.<sup>3,4</sup>

The third or final stage of repair is referred to as the Fontan procedure and attempts to dedicate the single ventricle to systemic circulation by redirecting flow from the inferior vena cava to the pulmonary artery. A consequence of the staging of the first two procedures can result in ventricular failure and pulmonary hypertension.<sup>3</sup> This cardiac catheterization and pulmonary artery stenting was an attempt to treat the pulmonary hypertension that was hindering this patient's upcoming cardiac reconstruction. Severe pulmonary hypertension is a contraindication to the Fontan procedure and this patient would not have been a candidate for further intervention without successful pulmonary artery stenting. During the Fontan procedure, hemodynamic status must be monitored closely. It is recommended that an arterial catheter be placed on the side contralateral to the shunt placement as vascular clamping during shunt placement will interfere with accurate monitoring.<sup>4</sup> PVR maintenance is of utmost importance as an increase in pulmonary blood flow can decrease systemic blood flow.<sup>4</sup> Avoidance of both high FiO<sub>2</sub> and hypercapnia is recommended to adequately maintain PVR.<sup>4</sup> Nitrous oxide and ketamine do not cause

elevations in PVR and are suggested agents.<sup>3,4</sup> Neuraxial anesthesia is also recommended for postoperative pain control.<sup>3,4</sup>

After the completion of surgical repairs, the anesthetic management is aimed at reducing PVR in order to increase pulmonary blood flow.<sup>5</sup> This can be accomplished with mild hypocarbia, low inspiratory pressures, alkalosis, and with administration of 100% FiO<sub>2</sub>.<sup>4</sup> Inhaled prostacyclins and nitric oxide may be necessary in severe cases.<sup>4</sup> After the Fontan procedure, pulmonary blood flow becomes passive and an increase in PVR will decrease venous return. Maintenance of adequate intravascular volume preserves pulmonary blood flow. Positive pressure ventilation will decrease PVR and it is recommended to provide a short inspiratory time, a prolonged expiratory time, larger tidal volumes, and a lower respiratory rate when placing a patient with this physiology on mechanical ventilation in order to promote pulmonary blood flow.<sup>4</sup> PEEP is beneficial in that it promotes alveolar recruitment, maintains functional residual capacity (FRC) and increases PaO<sub>2</sub>; however, it may also increase thoracic pressure which will decrease pulmonary blood flow.<sup>4</sup> A negative pressure cuirass device can be implemented in these patients when early extubation is not feasible and ventilatory assistance is necessary.<sup>4</sup> It is ideal in many anesthetic instances for the patient to maintain spontaneous respirations, however hypercarbia, decreased oxygenation, and atelectasis must be avoided as all increase PVR. In this case, the cardiologist requested neuromuscular blockade and therefore spontaneous ventilation was not possible. Mechanical ventilation was utilized without the addition of PEEP in an attempt to avoid an acute decrease in pulmonary blood flow.

It is important to note that each stage of palliation demands adjustments in anesthetic techniques. Proper management during one stage may prove detrimental at another stage. Full comprehension of the unique physiology as well as potential complications that present with each stage of palliation is necessary in order to provide the most appropriate anesthetic.

## References

1. Ahmad S, Lichtenthal P. Anesthetic management of a patient with a single ventricle and modified Fontan procedure. *J Cardiothorac Vasc Anesth.* 1993;7(6):727-729.
2. Ahmad S, Zengeya S, Kini U, et al. Familial isolated congenital Asplenia: case report and literature review. *Eur J Pediatr.* 2010; 169: 315-318.
3. Hosking MP, Benyan FM. The modified Fontan procedure: physiology and anesthetic implications. *J Cardiothorac Vasc Anesth.* 1992;6(4):465-475.
4. Leyvi G, Wasnick JD. Single-ventricle patient: pathophysiology and anesthetic management. *J Cardiothorac Vasc Anesth.* 2010;24(1):121-130.
5. Odegard K, McGowen F, DiNardo J, et al. Coagulation abnormalities in patients with single-ventricle physiology precede the Fontan procedure. *J Cardiothorac Vasc Anesth.* 2002;123:459-465.
6. Odegard K, McGowen F, Zurakowski D, et al. Coagulation factor abnormalities in patients with single-ventricle physiology immediately prior to the fontan procedure. *Ann Thorac Surg.* 2002;73: 1770-1777.
7. Ramamoorthy C, Haberkern C, Bhananker S, et al. Anesthesia-related cardiac arrest in children with heart disease: data from the pediatric perioperative cardiac arrest (POCA) Registry. *Anesth Analg.* 2010;110(5): 1376-1382.
8. Sparks W, Seefelder C, Shamberger R, et al. The perioperative management of a patient with complex single ventricle physiology and pheochromocytoma. *The International Anesthesia Research Society.* 2005;100: 972-975.
9. Walker SG, Stuth EA. Single-ventricle physiology: perioperative implications. *Semin Pediatr Surg.* 2004;13(3):188-202.

**Mentor:** Gary D. Clark, CRNA, EdD

Happy Holidays!



Vicki Coopmans, CRNA, PhD  
Editor